



# **Orthopantomography and use of Mandibular Indices for the Evaluation of Gender Distribution in Navi Mumbai Population - A Retrospective, Single Blind Study**

**Priyanka Vijay Patil<sup>1#</sup>, Manali Kulkarni<sup>1†</sup>, Sandeep Pagare<sup>1‡</sup>, Naveen Shetty<sup>1‡</sup>, Hemant Bhutani<sup>1#</sup> and Kapil Gavand<sup>1#</sup>**

<sup>1</sup>D. Y. Patil University School of Dentistry, Nerul, Navi Mumbai, India.

## **Authors' contributions**

*This work was carried out in collaboration among all authors. Author PVP, MK designed the study, performed the statistical analysis, wrote the protocol and wrote the first draft of the manuscript. Authors SP, NS and HBH managed the analyses of the study. Author KG managed the literature searches. All authors read and approved the final manuscript.*

## **Article Information**

DOI: 10.9734/JPRI/2021/v33i48B33264

### Editor(s):

(1) Paola Angelini, University of Perugia, Italy

### Reviewers:

(1) Ngeow Wei Cheong, University of Malaya, Malaysia.

(2) Muhammad Wasif Saleem, Chandka Medical College, Pakistan.

Complete Peer review History: <https://www.sdiarticle4.com/review-history/76518>

**Original Research Article**

**Received 27 August 2021**  
**Accepted 01 November 2021**  
**Published 08 November 2021**

## **ABSTRACT**

**Introduction:** The study of forensic sciences often leaves the forensic expert to draw conclusions from any and every material available in determining the identity of the deceased. The initial step in identifying a person is to determine their gender based on their adult skeleton. The human skeleton displays sexual dimorphism, of which the skull is most dimorphic providing an accurateness of 92%. However, in certain situations where the skull may not be found intact, the mandible plays a vital role. The mandible's thick covering of compact bone helps keep it from exploding during a mass tragedy. Dimorphism in the mandible is gender specific and is mainly reflected in its shape and size. The mandible is also easily radiographed and specific linear measurements of the mandibular rami as seen on an OPG are useful indices for gender determination.

**Aims:** To examine the efficacy of mandibular rami measures such as maximum ramus breadth, maximum ramus height, minimum ramus breadth, condylar height, coronoid height,

<sup>#</sup>Assistant Professor;

<sup>†</sup>Consultant Oral and Maxillofacial Radiologist;

<sup>‡</sup>Professor;

\*Corresponding author: E-mail: drpatilpriyanka16@gmail.com;

mandibular body length and gonial angles on the right and left side of an OPG in determining gender.

**Materials and methods:** 110 digital OPG's (55 males, 55 females) of a Navi Mumbai population were obtained retrospectively from a reputed dental college and hospital. The OPG's were taken using Xtropan 2000 OPG machine, 10x12 PSP plates, exposure parameters of 75 Kvp, 8 mas, 13 sec, and KODAK CR 7400 digitizer. Master View 3.0 software was used on the desktop computer to measure the mandibular ramus's width and thickness. Maximum ramus breadth, Maximum Ramus height and lowest ramus breadth of the mandibular rami, as well as the height of the condyle and the coronoid bone, and the length of the mandibular body and gonial angles on the right and left sides of the mouth, were all measured. Using a statistical formula, the measurements were substituted and gender was estimated.

**Result:** We used the IBM SPSS v 21.0 statistical software for social sciences to do our statistical study. p0.05 was deemed statistically significant, with a 5% margin of error and a 20% margin of error, giving the study an 80 percent power. In the study group, 51 of the 55 men were expected to be males, while 49 of the 55 females were anticipated to be females, while 6 of the 55 females were predicted to be males.

**Conclusion:** This research shows that the mandibular ramus is a useful tool for determining gender, and digital panoramic imaging yielded the best accurate linear measures. There was considerable sexual dimorphism in the mandibular ramus in the chosen Navi – Mumbai subpopulation, and the combination of 8 factors demonstrated an accuracy of 91.81 percent and was helpful for gender determination.

*Keywords: Gender determination; sexual dimorphism; mandibular ramus; orthopantomography; sexual dimorphism; there are several factors to consider while calculating these measurements: maximum ramus breadth, maximum ramus height and minimum ramus breadth are just a few examples.*

## 1. INTRODUCTION

People have an own identity in life, and forensic odontology relies heavily on the distinctive qualities and characteristics of teeth and jaws to identify both the living and the deceased. Teeth and bones may reveal a lot about a person's gender and age just by looking at them. If human skeletal remains are identified, it is an important first step in the investigation and identification procedure. Identification of age and gender pose certain difficulties in situations of mass disasters as it is based on the available remains of skeletal structures. In such situations of mass disasters where mangled remains are found, The Forensic Odontologist plays an important role in identifying the deceased's gender first, and subsequently age, since in adult skeletons, gender determination is the first stage in the identification procedure because following methods for estimating age and height are gender dependant. Skeletal elements are useful indicators of sex, age and race because they fulfil three basic criteria, namely. their morphology reflects anatomic and physiologic sex differences, they withstand the rigors of skeletonization and fossilization, they are recognizable throughout time.

If the whole adult skeleton is available for examination, age and gender can be established with 100 percent accuracy, but in mass catastrophes when fragmented bones are accessible, evaluation becomes problematic. Age and gender cannot be determined with 100 percent certainty. This means that the accuracy of gender identification is dependent on the completeness of the remains and the degree of sexual dimorphism present in the population. After the pelvis, the skull is the most dimorphic and easily sexable part of the skeleton, offering accuracy of up to 92 percent. The mandible, the biggest and strongest bone in the skull, may play an even more essential and vital role in gender determination in the absence of an entire skull. Because the mandible has such a thick covering of densely packed bone, it has a longer shelf life than most other bones<sup>1</sup>. Its physical characteristics fluctuate with respect to gender, race, and age.

The form and size of the mandible differ according to gender. The relative size, strength, and angulation of the masticatory muscles impact the appearance of mandibular dimorphism because the masticatory forces exerted differ across sexes. This influences shaping of the mandibular ramus. Hence male

mandibles tend to be bigger and more robust than female mandibles.

Forensic Odontologists use linear measures of the mandibular ramus and body, such as maximum ramus breadth, maximum ramus height, minimum ramus breadth, condylar height, coronoid height, the length of the mandibular body, and gonial angles on the right and left side, to create indices. These measures and morphometry-based methods are precise and can be used to identify a person's gender.

Researchers found that mandibular condyle and ramus are particularly sexually dimorphic because of the large morphological changes in size and remodeling that occur throughout growing in these areas.<sup>3</sup>

In dental, medical, and hospital clinics, dentofacial radiography has become a standard technique. The maxillofacial complex may be seen in great detail using rotational panoramic radiography, which is quite common. Forensic anthropologists use antemortem and postmortem radiograph comparisons to confirm the identity of human remains. This is a critical step in the identification process. When it comes to human remains identification, antemortem orthopantomography can be a lifesaver As well as the teeth, it gives you details on the jaw.

By giving good visibility of the mandibular ramus bilaterally and permitting specific measurements to establish sexual dimorphism, panoramic radiographs offer an excellent chance to research sexual dimorphism and age estimate in individuals.

Therefore it was decided that the goal of this research would be to see if other linear measures such as gonial angle and bigonial length digital panoramic radiograph were effective in determining gender in the Navi Mumbai subpopulation.

The following goals and objectives guided the design of this investigation.

It was the goal of the study to evaluate and assess the usefulness of mandibular linear measurements like maximum ramus breadth, maximum ramus height, minimum ramus height, condylar height, coronoid height, mandibular body length and gonial angles on the right and left side of an OPG in determining gender.

The study's goal was to find out the maximum and minimum ramus breadths, the maximum and minimum ramus heights, the coronoid height, the gonial angle, the bigonial width, and the mandibular body height in the premolar and molar areas of the OPG on the right and left sides, as well as to verify the accuracy of the formula provided in the literature for gender estimation and to assess its applicability in the Navi Mumbai subpopulation.

It was decided to include individuals with full dentition between the ages of 20 and 50 based on the results of an OPG examination. Patients with pathological fractures, deformities, or an edentulous jaw were excluded from the study, as were those with altered mandibular size as a result of developmental problems.

## 2. MATERIALS AND METHODS

It was possible to collect retrospective orthopantomography of 55 men and 55 women from the Navi Mumbai population who were between the ages of 20 and 50 years old from a well-known dental college and hospital. Radiographs had been taken using PSP plates (10x12) on Xtropan 2000 OPG machine, using exposure parameters of 75 Kvp, 8 mas, 13 sec, and KODAK CR 7400 digitizer. Measuring the mandibular ramus was done with the help of Master View 3.0 software.

The study was performed by 2 observers of whom one was blind to the gender of the individual.

Measurements were taken using a mouse-driven technique, as shown below (by dragging the mouse and creating lines through the digital panoramic radiograph using certain locations).

A- Maximum ramus breadth: The ramus' largest diameter, measured from the anterior to the posterior, is measured here. It is the distance between the mandibular ramus's most anterior point and a line extending from the condyle's most posterior point to the angle of the jaws.

B- Minimum ramus width: The ramus's anterior-posterior diameter is its smallest measurement. The distance between the mandibular ramus' most anterior point and a line connecting the angle of the jaw is called the ramus distance.

C- Maximum condylar height: The distance between the mandibular condyle's highest point to the mandible's lowest point is

D- Maximum height of the ramus: the point where the line from the condyle's highest

protrusion meets the bone's bottom margin

E- Maximum coronoid height: The projected distance between the coronoid and the bone's most inferior tip

F- Gonial angle: To determine the most inferior points, draw a line tangential to the ramus's posterior border and the condyle's lower border, as well as another line parallel to the gonial angle's inferior points. The gonial angle was created by crossing these lines at a point.

G- Bigonial width: It is the separation of two

goniophores. From the right to the left gonion, it is measured horizontally.

H- Using the distal side of the second premolar as a reference point, a vertical line was drawn from that point to the bottom border of the mandible's lower jaw.

A vertical line was drawn from the distal end of the 1st molar to the lower border of the jaw, and this was used to determine body height in the molar area.

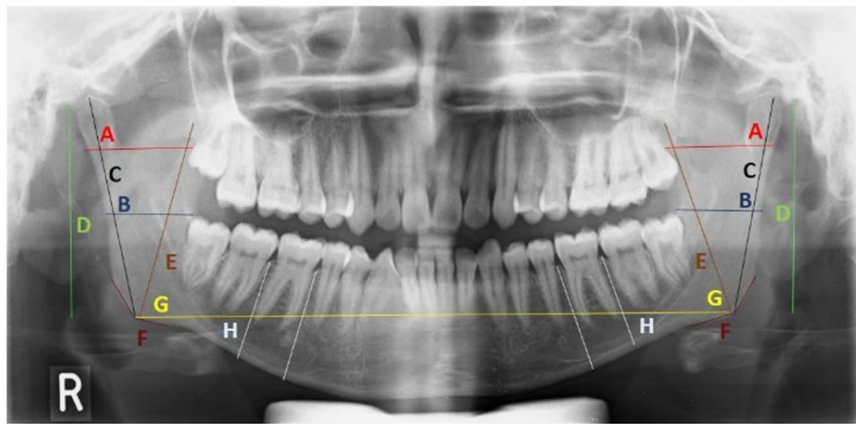


Fig. 1. X-Ray image teeth

Table 1. Actual age of the patient

	N	Minimum	Maximum	Mean	Std. Deviation
actual age	110	20	50	32.05	8.553

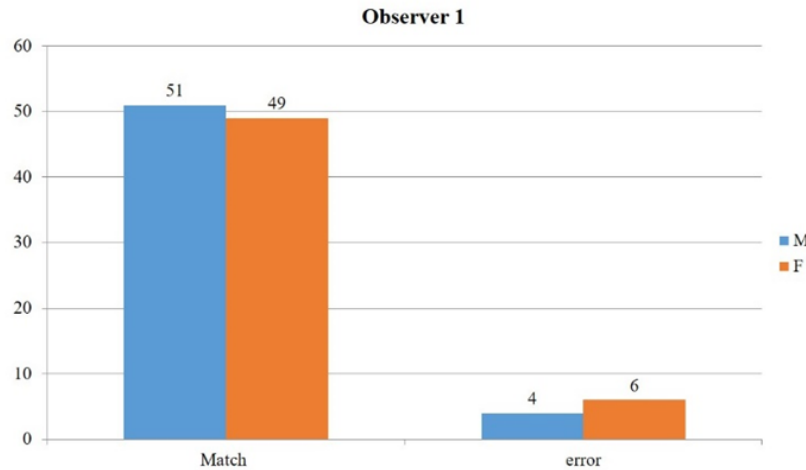
Table 2. Comparison of mean values of variables between males & females

	actual gender	N	Mean	Std. Deviation	Std. Error Mean	T value	p value of t test
Maximum	M	55	3.68	.246	.033	6.919	0.000**
Ramus Breadth	F	55	3.35	.255	.034		
Minimum	M	55	3.14	.271	.036	6.937	0.000**
Ramus breadth projective	F	55	2.88	.058	.008		
height of ramus	M	55	7.58	.529	.071	15.183	0.000**
Maximum	F	55	6.42	.207	.028		
height of	M	55	6.40	.474	.064	13.306	0.000**
Ramus	F	55	5.45	.239	.032		
Maximum	M	55	6.91	.458	.062	11.946	0.000**
Coronoid height	F	55	6.11	.189	.025		
gonial angle	M	55	136.15	4.819	.650	8.142	0.000**
	F	55	130.66	1.321	.178		
Body height	M	55	3.52	.285	.038	5.558	0.000**
	F	55	3.23	.266	.036		
bigonial width	M	55	20.55	1.145	.154	6.369	0.000**
	F	55	19.38	.739	.100		

\* = statistically significant difference ( $p < 0.05$ ), \*\* = statistically highly significant difference ( $p < 0.01$ ), # = non significant difference ( $p > 0.05$ ) ... for all table

**Table 3. Observer 1: Here is the prediction group, showing that of the 55 men who were studied, 51 were projected to be men and 4 were anticipated to be females, whereas among the 55 female people 49 forecasted to be women and 6 were predicted to be males**

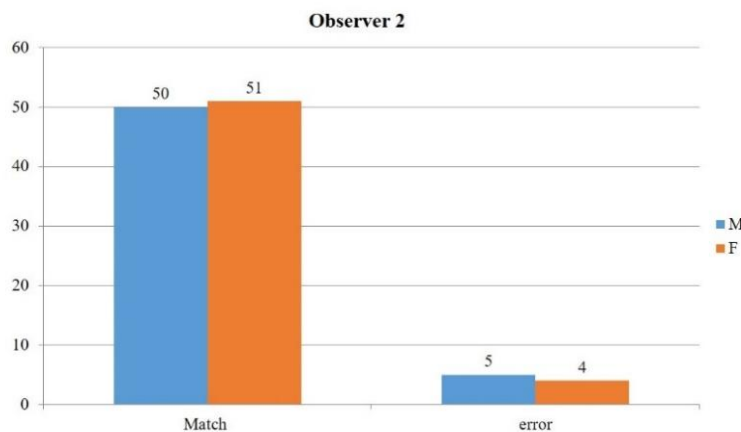
Actual gender	Total	Predicted		Accuracy%
		Match	Error	
M	55	51	4	90.90 %
F	55	49	6	



**Fig. 2. Match and error characteristics observation 1**

**Table 4. Observer 2: According to this table, 50 of the 55 men included in the study were expected to be men, while 5 were anticipated to be women, whereas 51 were predicted to be women and 4 were predicted to be men in the study group of 55 females**

Actual gender	Total	Predicted		Accuracy %
		Match	Error	
M	55	50	5	91.81%
F	55	51	4	



**Fig. 3. Match and error characteristics for observation 2**

### 3. RESULTS

An MS Office Excel Sheet was used to assemble the collected data (v 2010). To analyses the data, we used the Statistical Package for the Social Sciences (SPSS) (SPSS v 21.0, IBM). Descriptive statistics of categorical data has been depicted as frequencies & percentages, while that of numerical variables as mean & SD. Comparison of mean values of variables between males & females was done using t test. Using the regression equation mentioned in the parent article, accuracy of the formula was checked for predicting males and females using a cutoff set by sectioning point. Because the study's error rate was set at 5 percent and the study's power was set at 80 percent, any test with a result of p0.05 was considered statistically significant.

The anticipated mean difference and Standard deviation figures from the literature were used to calculate the sample size.

$$n = \frac{2(Z\alpha + Z\beta)^2 (s)^2}{d^2}$$

“where  $Z\alpha$  is the z variate of alpha error i.e. a constant with value 1.96,  $Z\beta$  is the z variate of beta error i.e. a constant with value 0.84, S, d is standard deviation and mean differences, values of which are taken from the parent article.”

The participants in the present study ranged from 20 to 50 years with an equal number of males and females (n = 110). Mean age of the subjects was 32.05 + 8.553.

In all, men had an average maximum ramus breadth of 3.68 cm, while females had an average of 3.35 cm. When comparing males and females, the mean minimum Ramus width was found to be 3.14 in men and 2.88 in women. For the projective height of ramus the total mean of 7.58 ± 0.529 in males, in females it was 6.42 ± 0.207 was seen. The total mean of maximum height of Ramus in males was 6.40 ± 0.474 and in females it was 5.45 ± 0.239. Maximum Coronoid height the total mean in males was 6.91 ± 0.458 and in females was 6.11 ± 0.189. The total mean of gonial angle was 136.15 ± 4.819 in males, in females was 130.66 ± 1.321. When it came to body height, men were 3.52 0.285 inches tall at the molar and premaxillary points. It was 3.23 0.266 among women. A

man's bigonial breadth was an average of 20.55 inches, while a woman's was a little smaller 19.38 inches. P0.01 showed a statistically significant difference between gender in the means of all variables, with mean values for all dimensions greater in men than in women.

Calculations based on the equations below might be used to estimate the gender of the data.1

DMale:  $-258.432 + 4.306$  (maximum ramus breadth)  $- 3.334$  (minimum ramus breadth)  $+ 7.139$  (maximum ramus height)  $- 3.856$  (projective height of ramus)  $- 1.328$  (coronoid height)  $+ 0.326$  (bigonial angle)  $+ 1.511$  (bigonial width)

DFemale:  $-228.555 + 3.743$  (maximum ramus width)  $- 2.689$  (minimum ramus width)  $+ 6.618$  (maximum ramus height)  $- 3.759$  (projective ramus height)  $- 1.239$  (coronoid height)  $+ 0.298$  (bigonial angle)  $+ 1.485$  (bigonial width).

The formula's accuracy in predicting men and females was tested by sectioning point -0.926 to determine the cutoff value. Males and females were separated at the sectioning point.

### 4. DISCUSSION

Using dental records and jaw fragments, one may make an educated guess as to someone is gender. However, approaches that are based on measurements and morphometry are accurate and may be used to estimate gender from the skull rather than morphological markers when trying to determine gender. One, they are pretty, and two, they are useful for research. Two things stand out about this element: first, there are not many standards that make use of it, and second, the bone is frequently found to be entirely undamaged [1].

Mandibular Dimorphism is a potential tool in gender determination, Males and females have different mandibular development phases, growth rates, and durations. The mandibular ramus provides the investigator with specific linear measurements or indices which can be standardized in linear regressive equations.

Panoramic radiography has been proven to be accurate for obtaining anatomically correct measurements. Orthopantomograph is frequently used by physicians as a screening tool for the identification of oral disorders and is commonly promoted. There are several advantages to using panoramic pictures,

including the large area covered, the minimal radiation dosage received by the patient, and the quick turnaround time. Other advantages include the fact that overlaid pictures do not conflict, and that contrast, brightness augmentation, and image expansion give an accurate and repeatable means of measuring the selected spots. Magnification and geometric distortion are drawbacks; the vertical dimension is somewhat distorted in comparison to the horizontal dimension, and this approach is extremely vulnerable to placement mistakes due to the relatively small picture layer that is used [1].

Damera et al in 2016 evaluated measurements of mandibular ramus on OPG and proposed a regression equation and concluded the measurements were highly accurate in determining the gender<sup>1</sup>. Our study calculated the mandibular ramus measurements using the regression formula given by Damera et al in estimating gender of our study population with an accuracy of 90.90%.

For example, in 2017, Sandeepa and colleagues looked at Mandibular Indices for Gender Prediction in the Saudi Population and found that the accuracy was as high as 92.75% with 9 parameters. They also found that the Mandibular Ramus exhibits high sexual dimorphism and was found to be useful in sex estimation [2].

Using an orthopantomography to measure the mandibular ramus, Annamalai Ponnuswamy et colleagues in 2012 came to the conclusion that the mandibular ramus provides significant evidence showing that the ramus may be utilized for gender determination in forensic investigation [3].

In 2013, James D. Raj and Sindhu Ramesh did a study on the dried adult mandibles of the South Indian population and discovered that the ramus displays considerable sexual dimorphism in this group [4].

Morphometric analysis of the mandibular ramus for digital orthopantomogram sex determination was performed by Chandramani More et al in 2017 and the overall accuracy for diagnosing sex was reported to be 69%, while the accuracy for diagnosing male and female was reported to be 68% and 70%, respectively. Mandibular ramus measures made with OPG are useful in determining sex, as a result [5].

Panoramic radiographs are useful in this context for the gender determination which can be a very

easy tool for forensic evaluation of a particular case. The evaluation also included very simple indices so that the person evaluating is also having no difficulties in the procedure. Thus this becomes a very good tool for gender determination.

## 5. CONCLUSION

Victims of mass disasters often go unrecognized due to lack of material available on site, thus challenging the forensic expert to think beyond his means. "When all else fails, the teeth and bones prevail".Mandible, the largest bone of the skull, is most resistant to damage and disintegration, and, believe it to be an important tool for determining gender. It provides measurements that are gender specific and reliable in gender determination.This study proves that mandibular indices are a reliable tool parameters for gender determination in Forensic Odontology.

## CONSENT

As per international standard or university standard, patients' written consent has been collected and preserved by the author(s).

## ETHICAL APPROVALS

We conducted our research after obtaining proper IEC approval.

## COMPETING INTERESTS

Authors have declared that no competing interests exist.

## REFERENCES

1. AjitDamera, JonnalaMohanalakshmi, Pavan Kumar Yellarthi, Begum Mohammed Rezwana. Radiographic evaluation of mandibular ramus for gender estimation: Retrospective study. Journal of Forensic Dental Sciences. 2016;8(2):74-78
2. Sandeepa NC, AtheerAbdulahdeGanem, Wala Abdullah Alqhtani, Yosra Mohammad Mousa, Eman Khalid Abdullah, and Afnan Hassan Alkhayri. Mandibular Indices for Gender Prediction: A Retrospective Radiographic Study in Saudi Population. J Dent Oral Health. 2017;3(9):1-7
3. Annamalai Ponnuswamy Indira, Archana Markande, Maria P David. Mandibular

- ramus: An indicator for sex determination – A digital radiographic study. Journal of Forensic Dental Sciences, Journal of Forensic Dental Sciences. 2012;4(2): 58-62
4. James D. Raj and Sindhu Ramesh. Sexual Dimorphism in Mandibular Ramus of South Indian Population, Journal of Anthropology. 2013; 9(2):253-258.
  5. ChandramaniBhagwan More, Ritika Vijayvargiya, NairitaSaha. Morphometric analysis of mandibular ramus for sex determination on digital Orthopantomogram. Journal of Forensic Dental Sciences. 2017;9(1): 1-5.

---

© 2021 Patil et al.; This is an Open Access article distributed under the terms of the Creative Commons Attribution License (<http://creativecommons.org/licenses/by/4.0>), which permits unrestricted use, distribution, and reproduction in any medium, provided the original work is properly cited.

*Peer-review history:*  
The peer review history for this paper can be accessed here:  
<https://www.sdiarticle4.com/review-history/76518>