

Common Modalities of Reconstruction for Scrotal Defects at a Tertiary Care Hospital in Eastern India: An Observational Study

GOURANGA DUTTA¹, ABHISHEK KUMAR RAI², MANOJ KUMAR SINGH³, RUPNARAYAN BHATTACHARYA⁴

ABSTRACT

Introduction: Scrotal reconstruction remains a challenging problem to the surgeons. The various techniques used for scrotal reconstruction includes residual tissue re-arrangement, skin grafts, pedicled and free tissue transfer. There is lack of unified approach to deal with the issue.

Aim: To discuss the surgical techniques performed for scrotal reconstruction in a tertiary care centre along with its epidemiological factors.

Materials and Methods: This observational descriptive study was conducted on 33 cases in a tertiary care centre located in Eastern India over a period of three years. Scrotal reconstruction was planned according to aetiology, defect size, associated co-morbidity and age of the patient. Evaluation to assess the efficacy of each procedure was done with patient's satisfaction scoring. At the time of discharge, with simple four level Likert scale, patient's satisfaction was assessed. Descriptive statistics

was used and results were expressed in terms of frequency and percentage.

Results: The mean age of the patients with scrotal defects was 48 ± 15.98 years. Fournier's gangrene ($n=21$) was the leading cause of scrotal defects followed by trauma ($n=8$). The most common scrotal defect size was 50-75% ($n=12$). The most common scrotal reconstruction performed was Pudendal artery flap (Singapore flap) ($n=12$). Donor site scar was limited and acceptable. Wound related complications detected clinically as partial tissue necrosis, was observed in two cases. Most patients were satisfied with the final outcome, assessed by Likert scale.

Conclusion: Scrotal reconstruction should be performed taking in account its aetiology, associated co-morbidity, age and the scrotal defect size. Aesthetically and psychologically, well planned flap is reliable and better in comparison to Split-Thickness Skin Graft (STSG) and most of the complications can be managed conservatively.

Keywords: Fournier's gangrene, Scrotal reconstruction, Singapore flap

INTRODUCTION

Scrotal reconstruction remains a challenging problem to the surgeons. The common cause of scrotal defects includes Fournier's gangrene, post-traumatic, benign and malignant neoplasms, thermal injuries etc., [1]. Scrotal defects are a source of morbidity and of great concern to the patients inflicted with this problem. The various techniques used for scrotal reconstruction includes residual tissue re-arrangement, skin grafts, pedicled and free tissue transfer [2-5]. At present, there are many reconstruction techniques described but there is lack of unified simple approach toward this morbid condition. The question is, what should be the approach and technique to follow that will provide the functional and acceptable aesthetic coverage of testis with minimum donor morbidity.

The ideal reconstruction procedure should provide friction less tissues with minimum donor tissue morbidity, which can maintain both its form (cosmetic appearance) and function (thermoregulation). The reconstruction technique should be individualised in each case taking into account the various factors- size of the defect, associated co-morbidities, surgeon and patients preference, and the family status of the patient. With the availability of wide range of donor tissues, ranging from local to free flap, extensive scrotal defects are managed with ease, nowadays.

The objectives of this study was to discuss the options for the reconstruction of the scrotal defects, describe the epidemiological factors and to assess the surgical complications.

MATERIALS AND METHODS

This observational descriptive study was carried out at Plastic and Reconstructive Surgery Department of a tertiary care government institution in Kolkata, from November 2017 to October 2020. Approval from the Departmental Ethical Committee was taken (RGK- PLASTIC-160/17) and written consent was obtained from

all participants during the study. Scrotal defects of various sizes included in the study, from small to complete scrotal tissue loss. The total sample size considered was 33 cases after examining for all the below mentioned criteria.

Inclusion criteria: Patients with scrotal mass/defects or those patients with exposed testis presented in Plastic surgery Outpatient Department or Inpatient Department referral from other departments during the study period were included.

Exclusion criteria: Patients with inguinal hernia, malignancy, immunocompromised patients and those who did not give informed consent were excluded from the study.

Study Procedure

Following factors were considered while choosing options for scrotal reconstruction:

- 1) Age of the patient- Young patients were managed aggressively for coverage whereas patients in extremes of ages were managed more conservatively or with simpler technique.
- 2) Associated co-morbidity- Simpler options like grafting or local tissue rearrangements were preferred in patients with one or more co-morbidity.
- 3) Testicular function- In patients whose family was not yet completed, in that remaining scrotal tissue rearrangement was preferred.
- 4) Viability of adjacent skin- Viable part of scrotal tissue was saved for delayed coverage during debridement.
- 5) Associated injuries- Perineal or groin injury limits local fasciocutaneous flap due to donor area scarring.
- 6) Severity/percentage of scrotal skin loss- Scrotal skin loss was assessed at the time of coverage. For setting standard approach and unambiguous assessment scrotal defect size

was divided into four groups according to percentage of scrotal skin loss: <25%, 25-50%, 50-75% and >75%.

Majority of the patients underwent delayed reconstruction, before which they were treated with serial debridement and regular dressings until the condition of the patient and the wound were optimised. Immediate reconstruction was performed only after debulking of scrotal lymphoedema and in congenital bifid scrotum.

Fournier's gangrene constitutes majority of the bulk. Almost all the patients presented with co-morbidities either with diabetes or alcoholism or advanced age. These patients were primarily treated with serial debridement and regular dressings, along with control of hyperglycaemia and infection [6-8]. According to the condition of the wound and the patient, further line of treatment was then planned. For larger wound and sick patients, Vacuum Assisted Closure Therapy (VAC) was done after debridement and changed according to the amount of exudate on every 4th or 5th day. Only after the wound matures and patient condition stabilise, definitive reconstruction was performed.

Traumatic loss of scrotal tissue was next in aetiology. Patients were stabilised in trauma ER. Most of the wounds were contaminated and thorough lavage was performed. Watchful delayed debridement of devitalised scrotal soft tissue and skin was then performed, as there was risk of overzealous excision of tissue with doubtful vascularity. Once line of demarcation appears, only then further debridement was performed. Complete tissue loss of the scrotum with minimal contamination was the cases for early reconstruction.

Different Scrotal Reconstruction Techniques

1. Healing by secondary intention

Usually preferred in patients with loss of <25% of scrotal tissue or in patients who were unfit to undergo any surgical intervention. Typical defects were less than 1.5 cm.

2. Direct closure/local tissue adjustment

The viscoelastic property of the scrotal tissue allows for primary closure of the defect [9,10]. Study shows up to 60% of scrotal defects can be closed directly or with residual scrotal tissue re-arrangement [11].

3. Partial-thickness skin graft

Usually preferred in scrotal defects with healthy granulation with or without dartos. STSG can also be done in patients whose family was complete or in old aged patients with multiple comorbidities.

4. Scrotal/perineal advancement flaps

The scrotal defects can be closed by local tissue rearrangement which includes closure by V-Y advancement, transposition or rotation flaps. The donor site can be closed primarily or with partial-skin thickness graft.

5. Singapore flap

These fascio-cutaneous flaps were based on pudendal artery. Unilateral and bilateral Singapore flap was used to cover >50% loss of scrotal tissue.

6. Medial thigh flap

Usually preferred in patients with >50% loss of scrotal tissue. Donor sites were closed primarily.

7. Free flaps

Usually preferred in young patients in which there was loss of scrotum as well as surrounding tissues.

These patients were treated with appropriate reconstruction technique according to defect size, surgeon's preference and patient's choice [1]. Clinical photograph pre, intra and postoperatively were obtained and evaluated for aesthetic outcome. Any complication of surgical procedure noted and delt accordingly. Evaluation to assess the efficacy of each procedure was done with patient's satisfaction scoring. At the time of discharge with simple 4 level Likert scale [12], patient's satisfaction was assessed.

STATISTICAL ANALYSIS

Statistical analysis was done with simple descriptive measures like frequency, percentage, central tendency and dispersion using categorical and continuous data.

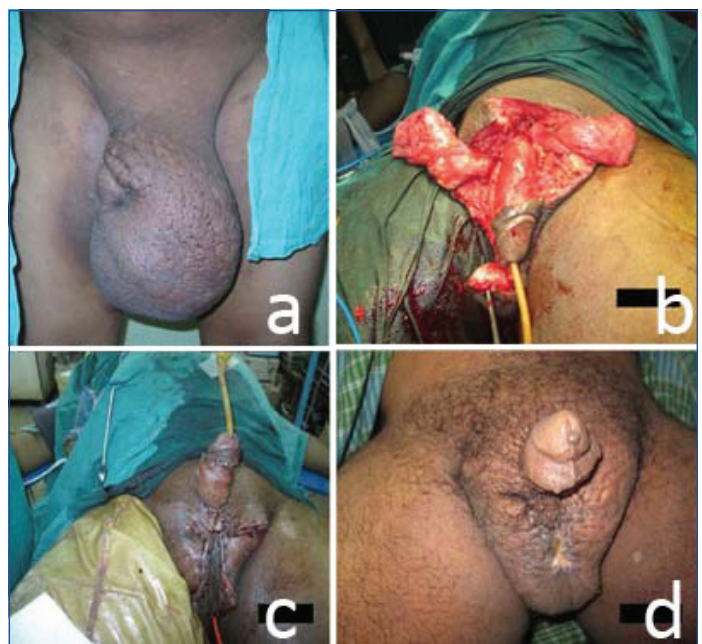RESULTS

In the present study, over a period of three years, a total of 33 patients were examined. Scrotal reconstruction was performed in four groups. Majority of scrotal defects were caused by Fournier's gangrene (n=21, 63.63%). Trauma was the second most common cause of scrotal tissue loss (n=8, 24.24%), followed by scrotal lymphoedema resection (n=3, 9.1%) and congenital bifid scrotum (n=1, 3.03%) in descending order.

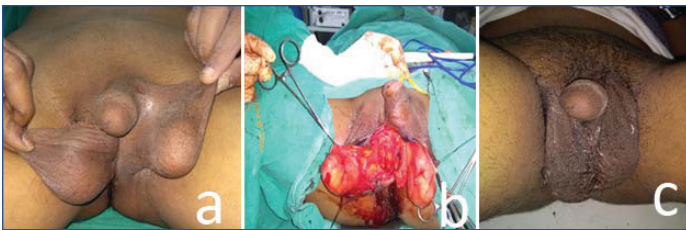
The minimum and maximum age included in the present study was 17 and 68 years. The mean age comes out to be 48±15.98 years. The most common associated co-morbidity in patients with scrotal defects was diabetes mellitus (n=22, 66.67%) whereas alcohol addiction was present in (n=9, 27.27%) patients.

During calculation of defect size, scrotal lymphoedema and congenital bifid scrotum were excluded as these cases have adequate skin for coverage, so the effective number of scrotal defects in consideration was 29 cases. The most common scrotal defect size at the time of reconstruction was 50-75% of scrotum (n=12, 41.38%). Next to follow is >75% of scrotal tissue loss (n=8, 27.59%), then 25-50% scrotal defects (n=6, 20.69%) and the least common is <25% loss of scrotum tissue (n=3, 10.34%).

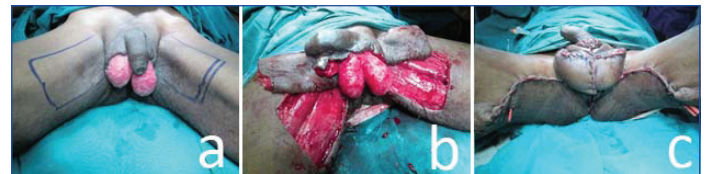The time interval between initial presentation and final reconstruction is highest for the patients with Fournier's gangrene followed by patients with traumatic loss of scrotal tissue. Early reconstruction performed in three cases where patients were optimised. Rest of the cases were dressed regularly with normal saline till the wound matures. Elective surgical reconstruction planned for rest of the cases. Debulking of scrotum was performed in scrotal lymphoedema. In all the cases corrugated drain were used. In one case that was associated with Ram's horn penis, penile degloving and STSG was done along with scrotal debulking [Table/Fig-1]. Congenital bifid scrotum was treated with by Z-plasty [Table/Fig-2]. Tunica vaginalis was open and everted bilaterally and septum created by attaching both the testis. Closure was done with anterior and posterior multiple z-plasty with skin and dartos in one layer.



[Table/Fig-1]: a) Top left- Scrotal lymphoedema with buried penis; b) Top right- After debulking scrotum and degloving the penis; c) Bottom left- Immediate postoperative pictures of neo-scrotum and grafted penile shaft; d) Bottom right- 3 months Postop.



[Table/Fig-2]: a) Left- Bifid scrotum in an adult patient; b) Middle- After pairing with multiple zigzag incision with exposed testis; c) Right- After one month postop.

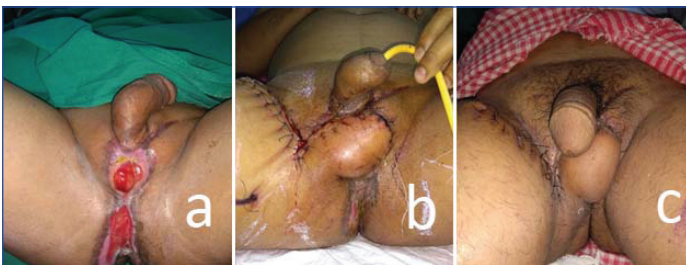

[Table/Fig-6]: a) Left- >75% loss of scrotum following debridement with marked bilateral medial thigh flaps in a Fournier's gangrene patient; b) Middle- Debridement of the raw area and harvested flaps; c) Right- Good coverage achieved after inset of the flaps and donor site closed primarily.

The most common scrotal reconstruction procedure performed in the present study was Singapore flap [Table/Fig-3]. According to the defect size and laxity of local tissue, unilateral and bilateral Singapore flap done for the patients, followed by local tissue arrangements, STSG and other local fasciocutaneous flaps. Unilateral or bilateral medial thigh flap and local random flaps included in other local fasciocutaneous flaps. Scrotal debulking and primary z-plasty closure included in the local tissue arrangements along with cases of scrotal tissue loss which were managed with adjustment of remaining scrotal tissue. Two patients were allowed to heal by secondary intention [Table/Fig-4-7].

Techniques	Scrotal defects	Number of cases encountered (n=33 cases)	Total (%)
Singapore flap	Unilateral	5	36.36
	Bilateral	7	
Other fasciocutaneous flap		4	12.12
Local tissue arrangements	Adjustment with available scrotal tissue	5	27.27
	Scrotal debulking in lymphoedema	3	
	Z-plasty and primary closure	1	
Split-thickness skin graft	Split-thickness skin graft	6	18.18
Healing with secondary intention	Healing with secondary intention	2	6.06

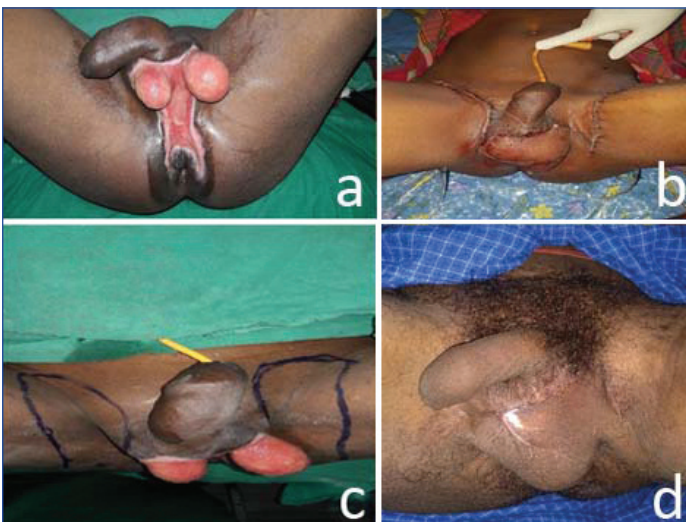
[Table/Fig-7]: Procedures performed for reconstruction.



[Table/Fig-3]: a) Left- Traumatic loss of scrotum >75% with exposed testis with perineal wound; b) Middle- Right sided Singapore flap done to cover the scrotum and skin graft for perineal wound; c) Right- Three weeks postop showing that flap is well settled.

by debridement and STSG. Both patients were follow-up case of Fournier's gangrene and both are diabetic. Time of recovery was calculated from time since final reconstruction to discharge from the hospital. It was maximum in Fournier's gangrene patients and minimum in patients with congenital bifid scrotum.

Except two patients, rest were psychologically satisfied or very satisfied with the outcome [Table/Fig-8]. The donor sites were closed directly in all cases of fasciocutaneous flaps without significant donor site morbidity. Protective sensation was found to be present, although less. None of our patient required urinary or colonic diversion.



[Table/Fig-4]: a) Top left- >75% loss of scrotum with large perineal wound following debridement of Fournier's gangrene; b) Bottom left- Bilateral Singapore flaps marked; c) Top right- Immediate postop showing good coverage of the scrotum and perineum and donor sites closed primarily; d) Bottom right- well-formed scrotum at six months.

Linguistic expression	Number of patients
Very satisfied	22
Satisfied	9
Dissatisfied	2
Very dissatisfied	0

[Table/Fig-8]: Satisfaction scoring.

DISCUSSION

In present study, Fournier's gangrene was responsible for maximum scrotal defects and other aetiologies also are in accordance to the study done by William Knight and Goodwin-Walters [1]. The mean age was found to be 48.03 years which is supported by the study done by Daniel Franscisco (mean age 48.9 years). Diabetes mellitus was the most common co-morbidity in patients and bulk of them are of Fournier's gangrene (95.24%) which is in accordance to the study done by Lahham SA et al., [13,14].

The most common scrotal defect size, presented for reconstruction was 50-75%. The time duration between first presentation and final procedure was maximum in Fournier's gangrene patients, which is supported by the study done by Robert knight [1].

While choosing flaps, internal pudendal artery flap was the first preference when donor area is virgin. The reason being easy dissection, reliable flap, blood loss is less compared to medial thigh flap and donor area scar is well hidden. To cover more area it is preferable to harvest bilateral flap instead of longer and wider unilateral flap. This minimises flap margin necrosis as well as donor site complications like difficult closure, dehiscence and bad scarring.

Two patients suffered marginal tissue loss one of them was partial skin necrosis near suture line in debulked skin of scrotal lymphoedema. One patient suffered partial Singapore flap loss which was managed

The skin grafts are moistureless and undergoes contraction in long run. The aesthetic outcome can be unsatisfactory and the skin grafts provides minimum resistance to the local shearing forces due to loss of tissue components [15,16]. From continuous friction of thigh, hypersensitivity and itching may occur which in turn leads to infection and oedema. However, skin grafts may be quite handy in co-morbid patients and can result in satisfactory outcome as they have their own advantages over flap reconstruction [2,17]. It also keeps the testicular temperature cool compared to any flaps.

Flap reconstruction provides tissues which have good resistance to the shearing forces of the thigh and better protection to the underlying testis. Cosmetic acceptance was greater in patients with flap reconstruction due to its resemblance to the lost scrotal tissues on long term follow-up. Protective sensation was better than skin grafts.

In scrotal lymphoedema, there are studies that suggests to remove all the oedematous skin and subcutaneous tissue along with lymphatic channels and coverage with skin graft directly over scrotum, but we preferred reconstruction like with like tissue. In this study, scrotal lymphoedema delt with debulking of the edematous skin and subcutaneous tissue keeping two lateral flaps and posterior flap according to vascularity of scrotum, with fair outcome [11].

When exposed, both testicles were always attached to prevent torsion either before grafting or before any flap surgery thereby minimising morbidity as shown in Hofer MD et al., [11]. In this study, the testis were not put in the thigh pocket either temporary or permanently as mentioned in some articles where there is difficulty in closure [11].

Regarding choice of procedure, it is prudent to estimate the defect size in first hand whether it is more than 50% or less. If more than 50%, additional tissues need to be incorporated in the form of graft or flap. Defects that constitute <50% of scrotal tissue loss and without any additional perineal defect can be managed with scrotal flap mobilisation or with available scrotal tissue re-arrangements. Although, this is only a rough outline, final assessment of the coverage plans always made intraoperatively after proper debridement, as due to chronic inflammation tissue thickness, pliability and stretchability may be compromised and additional procedure may be required. Usually, complications are minor and can be delt with minor intervention or simply with dressings.

In this study, no free flaps were done. All the scrotal defects can be addressed effectively with locoregional flaps. It reduces both operating time and donor site morbidity. None of the defect is large enough to limit the local flaps thereby negate the need of free flaps. Further studies will be needed to assess the testicular function which is presently beyond the scope of present paper. Further study with long term results including more number of sample size will be required to overcome these limitations.

Limitation(s)

Firstly, the study is limited by smaller number of study participants and potential selection bias, which in term limits the generalisability. Secondly, very long term follow-up is not assessed here to definitely state the outcome in future. Third limitation is that testicular functional aspects, which could not be assessed as the study samples are of different age groups and beyond our scope.

CONCLUSION(S)

Flap reconstruction or STSG is recommended for defects >50% of scrotum whereas local tissue re-arrangement preferred in scrotal defects of <50%. Aesthetically and psychologically, well planned flap is reliable and better in comparison to STSG. Most of the complications can be managed conservatively.

REFERENCES

- [1] Khan Q, John R. Scrotal reconstruction: A review and a proposed algorithm. *Eur J Plast Surg.* 2013;36:399-406.
- [2] Hesselheldt-Nielsen J, Bang-Jensen E, Riegels-Nielsen P. Scrotal reconstruction after Fournier's gangrene. *Ann Plast Surg.* 1986;17(4):310-16.
- [3] Millard DR Jr, Scrotal construction and reconstruction. *Plast Reconstr Surg.* 1966;38(1):10-15.
- [4] Gudaviciene D, Milonas D. Scrotal reconstruction using thigh pedicled flaps after scrotal skin avulsion. *Urol Int.* 2008;81(1):122-24.
- [5] Ng D, Tang CB, Kadirkamanathan SS, Tare M. Scrotal reconstruction with a free greater omental flap: A case report. *Microsurgery.* 2010;30(5):410-13.
- [6] Chen SY, Fu JP, Chen TM, Chen SG. Reconstruction of scrotal and perineal defects in Fournier's gangrene. *J Plastic Reconstr Aesthet Surg.* 2011;64(4):528-34.
- [7] Ferreira PC, Reis JC, Amarante JM, Silva AC, Pinho CJ, Oliveira IC, et al. Fournier's gangrene: A review of 43 reconstructive cases. *Plast Reconstr Surg.* 2007;119(1):175-84.
- [8] Cuccia G, Mucciardi G, Morgia G, Stagno d'Alcontres F, Gali A, Cotrufo S, et al. Vacuum-assisted closure for the treatment of Fournier's gangrene. *Urol Int.* 2009;82(4):426-31.
- [9] Tan BK, Rasheed MZ, Wu WTL. Scrotal reconstruction by testicular apposition and wrap-around skin grafting. *J Plastic Reconstr Aesthet Surg.* 2011;64(7):944-48.
- [10] Bothra R, Bhat A, Saxena G, Chaudhary G, Narang V. Dog bite injuries of genitalia in male infant and children. *Urol Ann.* 2011;3(3):167-69.
- [11] Hofer MD, Dumanian GA, Felício J, Martins FE. Updates in the management of benign and malignant scrotal conditions: Issues on surgical ablation and reconstruction. *AME Med J.* 2020;5:27.
- [12] Allen, Elaine; Seaman, Christopher. *Likert Scales and Data Analyses.* Quality Progress. 2007. Pp. 64-65.
- [13] Mello DF, Helene A Jr. Scrotal reconstruction with superomedial fasciocutaneous thigh flap. *Rev Col Bras Cir.* 2018;45(1):e1389.
- [14] Lahham SA, Sequina AJMA-S, Mohammedali S. Versatility of Singapore flaps in the reconstruction of scrotal defects. *J Gen Surg.* 2018;2:02-04.
- [15] Hsu H, Lin CM, Sun TB, Cheng LF, Chien SH. Unilateral gracilis myofascio cutaneous advancement flap for single stage reconstruction of scrotal and perineal defects. *J Plast Reconstr Aesthet Surg.* 2007;60(9):1055-59.
- [16] Gomes CM, Ribeiro-Filho L, Giron AM, Mitre AI, Figueira ER, Arap S. Genital trauma due to animal bites. *J Urol.* 2001;165(1):80-83.
- [17] Maguina P, Palmieri TL, Greenhalgh DG. Split thickness skin grafting for recreation of the scrotum following Fournier's gangrene. *Burns.* 2003;29(8):857-62.

PARTICULARS OF CONTRIBUTORS:

1. Assistant Professor, Department of Plastic Surgery, R G Kar Medical College and Hospital, Kolkata, West Bengal, India.
2. Senior Resident, Department of Plastic Surgery, R G Kar Medical College and Hospital, Kolkata, West Bengal, India.
3. Senior Resident, Department of Plastic Surgery, R G Kar Medical College and Hospital, Kolkata, West Bengal, India.
4. Professor, Department of Plastic Surgery, R G Kar Medical College and Hospital, Kolkata, West Bengal, India.

NAME, ADDRESS, E-MAIL ID OF THE CORRESPONDING AUTHOR:

Dr. Gouranga Dutta,
31, RN Tagore Road, Kolkata, West Bengal, India.
E-mail: gdutta24@gmail.com

AUTHOR DECLARATION:

- Financial or Other Competing Interests: None
- Was Ethics Committee Approval obtained for this study? Yes
- Was informed consent obtained from the subjects involved in the study? Yes
- For any images presented appropriate consent has been obtained from the subjects. Yes

PLAGIARISM CHECKING METHODS: [Jaain H et al.]

- Plagiarism X-checker: Sep 16, 2021
- Manual Googling: Jan 13, 2022
- iThenticate Software: Jan 29, 2022 (1%)

ETYMOLOGY: Author Origin

Date of Submission: **Sep 15, 2021**
Date of Peer Review: **Dec 17, 2021**
Date of Acceptance: **Jan 22, 2022**
Date of Publishing: **Feb 01, 2022**