



The Rosai-Dorfman Syndrome: A Case Report

**Nadia Mebrouk^{a*}, Najlae Attari^a,
Boutaina Halimi^a, Loubna Chtouki^a,
Najat Lamalmi^b and Abdelali Bentahila^a**

^a *Pediatric Unit P4, Children's Hospital of Rabat, CHU Ibn Sina, Mohamed V University, Rabat, Morocco.*

^b *Laboratory of Anatomy and Pathologic Cytology, CHU Ibn Sina, Mohamed V University, Rabat, Morocco.*

Authors' contributions

This work was carried out in collaboration among all authors. All authors read and approved the final manuscript.

Article Information

DOI: 10.9734/AJPR/2023/v12i2236

Open Peer Review History:

This journal follows the Advanced Open Peer Review policy. Identity of the Reviewers, Editor(s) and additional Reviewers, peer review comments, different versions of the manuscript, comments of the editors, etc are available here: <https://www.sdiarticle5.com/review-history/99027>

Case Study

Received: 18/02/2023

Accepted: 20/04/2023

Published: 20/04/2023

ABSTRACT

Sinus histiocytosis, also known as Rosai-Dorfman Syndrome (SRD), is a noncancerous condition that causes the growth of large masses of histiocytes in lymph nodes, primarily in the cervical area. Visceral damage is common, and diagnosis is made through histological examination. The cause of SRD is unknown and can occur at any age, even in children. The condition can sometimes improve spontaneously, but large tumor masses can cause compression and damage, particularly if they involve the retro-orbital or epidural areas. In most cases, it is best to avoid treatment, but therapeutic interventions may be necessary for forms of the disease that pose a direct threat or are progressing. Treatment is not standardized and may involve surgery, corticosteroids, immunosuppressants, and/or alpha interferon, depending on the individual case. We present a case study of a 4-year-old child who had multiple bilateral adenopathies. The diagnosis was verified through a biopsy of the lymph nodes.

*Corresponding author: Email: nadia.mebrouk@hotmail.com;

Keywords: Rosai dorfman syndrome; child; immunosuppressants.

1. INTRODUCTION

Rosai-Dorfman disease, also known as sinus histiocytosis with multiple polyadenopathies (SHMT), is a condition that involves the proliferation of histiocytes and has been recognized as a distinct clinical and pathological entity since it was first described by Rosai and Dorfman in 1969 and 1972 in two separate publications that reported 4 and 34 cases, respectively. The disease is rare and characterized by the presence of significant tumor masses in lymph nodes or other areas of the body (extra-nodal). Histologically, the disease is marked by massive infiltration of histiocytes in the sinuses of lymph nodes [1], and it belongs to the group of non-Langerhansian histiocytosis. In this context, we present a case study of a child with Rosai-Dorfman sinus histiocytosis.

2. CASE REPORT

The patient is a 6-year-old boy with no prior medical history who presented with painless bilateral submandibular cervical adenopathies that rapidly increased in size over a period of three weeks (Fig. 1). The patient also experienced fever, but the general state remained stable. The patient's clinical and ophthalmological examinations were normal. Laboratory tests showed an inflammatory syndrome with hypochromic microcytic anemia, hyperleukocytosis, an elevated sedimentation rate of 76 mm at the first hour, and a C-reactive protein level of 130 mg/L. Imaging tests revealed multiple bilateral cervical adenopathies, with the largest located in the left chain 2B measuring 17/18 mm, as well as multiple mediastinal and abdominal adenopathies (Fig. 2). Histological examination of a cervical lymphadenopathy revealed that the normal architecture of the lymph node parenchyma was erased by an accumulation of numerous histiocytes within the dilated sinuses. These histiocytes had large, rounded or oval, vesicular nuclei, nucleoli, and an abundant eosinophilic cytoplasm, and in some places, lympho-plasmocytes (emperipoise) were present (Figs. 3 and 4). Immunohistochemistry tests showed that anti-CD1a antibodies were negative in the histiocyte cells, while anti-CD68

antibodies and anti-S100 antibodies were positive in the histiocyte cells, and anti-CD3 and anti-CD20 antibodies were positive in the residual small lymphocytes (Figs. 5 and 6). The patient was diagnosed with Rosai-Dorfman histiocytosis, and due to the absence of signs of compression and the stable general condition of the patient, therapeutic abstention was chosen as the management option. Two weeks later, the patient returned to our unit with signs of compression, and we put him on oral treatment with corticosteroids.

3. DISCUSSION

Sinus histiocytosis with massive lymphadenopathy is a rare, benign disease that typically presents with the rapid onset of painless, bilateral cervical lymphadenopathy, although other lymph node sites may also be involved [2-5]. These adenopathies are generally bilateral and voluminous. Our patient presented with mediastinal and abdominal lymph node localization. An inflammatory syndrome is present in around two-thirds of cases, with neutrophilic polynucleosis [2,3] and polyclonal hypergammaglobulinemia being common [5,6]. Tuberculosis is a key differential diagnosis in our country, but other pathologies such as infections, hemopathies, and metastases can also be considered [7]. The diagnosis is confirmed by histological examination, which typically shows histiocytes grouped in islets, foam cells with lymphophagocytosis. In our patient, the histological study of a biopsy of a cervical lymph node confirmed the morphological aspect and immunohistochemical profile of Rosai-Dorfman disease. Therapeutic abstention is generally recommended in cases where the adenopathies are stable and not compressive [8]. Therapeutic indications must be reserved for the progressive tumoral forms or having a functional or vital threat. Management can range from radiotherapy and chemotherapy in the event of severe manifestations with risk of compression, surgery is indicated in immediately threatening forms and radiotherapy is only effective in one third of cases [9,8]. Local recurrences after surgery are however possible [3,10-12].

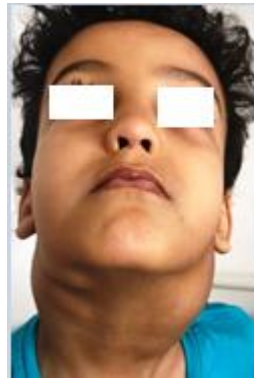

Fig. 1. Cervical adenopathies

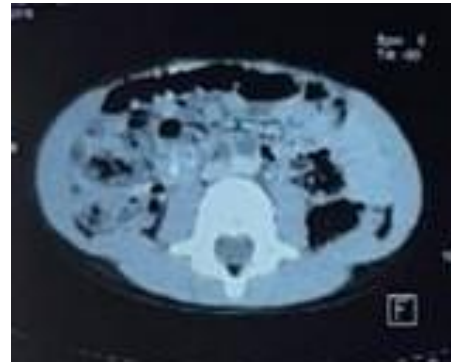
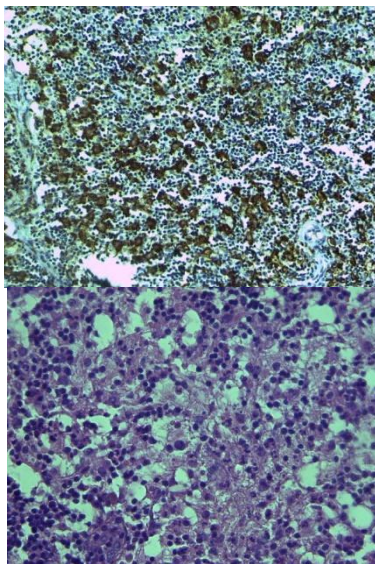
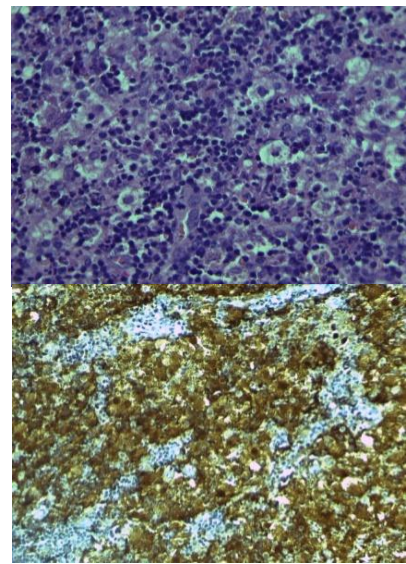


Fig. 2. Abdominal adenopathies



Figs. 3 and 4. HE (hemalin eosin) sections show massive infiltration of the sinuses by histiocytes with emperipoia



Figs. 5 and 6. Anti-CD163 and anti-S100 antibodies show positive immunostaining

4. CONCLUSION

Rosai-Dorfman disease is a rare cause of lymphadenopathy that must be differentiated from more common pathologies like lymph node tuberculosis and lymphoma. Therefore, a systematic biopsy should be performed when faced with any febrile polyadenopathy.

CONSENT

As per international standard or university standard, parental(s) written consent has been collected and preserved by the author(s).

ETHICAL APPROVAL

As per international standard or university standard written ethical approval has been collected and preserved by the author(s).

COMPETING INTERESTS

Authors have declared that no competing interests exist.

REFERENCES

1. Rosai J, Dorfman RF. Sinus histiocytosis with massive lymphadenopathy: A pseudolymphomatous benign disorder. Analysis of 34 cases. *Cancer* 1972;30(5): 1174–88.
2. Foucar E, Rosai J, Dorfman R. Sinus histiocytosis with massive lymphadenopathy (Rosai–Dorfman disease): Review of the entity. *Semin Diagn Pathol* 1990;7(1):19–73.
3. Galicier L, Fieschi C, Meignin V, Clauvel J-P, Oksenhendler E. [Rosai–Dorfman

- disease]. Presse Med. 2007;36(11 Pt 2):1669–75.
4. Galicier L, Fieschi C, Meignin V, Clauvel JP, Oksenhendler É. La maladie de ROSAI DORFMAN. Presse médicale. 2007;36: 1669–75.
 5. McClain KL, Natkunam Y, Swerdlow SH. A typical cellular disorders. Hematology Am Soc Hematol Educ Program. 2004;283–96.
 6. ElKohen A, Planquart X, Al Hamany Z, Bienvenu L, Kzadri M, Denis H. Sinus histiocytosis with massive lymphadenopathy (Rosai-Dorfman disease): Two case reports. International Journal of Pediatric Otorhinolaryngology. 2001;61: 243–2470
 7. Lasak JM, Mikaelian DO, Mccue P. Sinus histiocytosis: A rare cause of progressive pediatric cervical adenopathy. Otolaryngology–Head and Neck Surgery. 1999;120(5):765-9.
 8. Mebazaa A, Trabelsi S, Ghariani N, Sriha B, Belajouza C, Denguezli M, Noura R et coll. Histiocytose sinusale de « Rosai Dorfman » cutanée isolée de présentation clinique trompeuse. Ann DermatolVenereol. 2005;132:9S280-9S289.
 9. Omer Faruk Unal, Serap Koybasi, Sefa Kaya. Sinus histiocytosis with massive lymphadenopathy. International Journal of Pediatric Otorhinolaryngology. 1998;44(2):173-176.
 10. Karunanithi S, Singh H, Sharma P, Naswa N, Kumar R. 18F-FDG PET/CT imaging features of Rosai Dorfman disease: A rare cause of massive generalized lymphadenopathy. Clin Nucl Med 2014;39 (3):268–9.
 11. Fakhfakh W, Kharrat K, Elalaoui A. La maladie de ROSAI DORFMAN à localisation nasale à propos de deux cas. Journal Tunisiend' ORL Décembre; 2002.
 12. Pulsoni A, Anghel G, Falcucci P, Matera R, Pescarmona E, Ribersani M, et al. Treatment of sinus histiocytosis with massive lymphadenopathy (Rosai–Dorfman disease): Report of a case and literature review. Am J Hematol. 2002 ;69(1):67–71.

© 2023 Mebrouk et al.; This is an Open Access article distributed under the terms of the Creative Commons Attribution License (<http://creativecommons.org/licenses/by/4.0>), which permits unrestricted use, distribution, and reproduction in any medium, provided the original work is properly cited.

Peer-review history:

The peer review history for this paper can be accessed here:

<https://www.sdiarticle5.com/review-history/99027>