



The Paradox of Happy Hypoxia in COVID 19

Madhu Bansode^{1*} and Pankaj Bansode¹

¹*Symbiosis Medical College for Women, Symbiosis International (Deemed University), Pune, Maharashtra, India.*

Authors' contributions

This work was carried out in collaboration between both authors. Both authors read and approved the final manuscript.

Article Information

DOI: 10.9734/JPRI/2021/v33i38A32066

Editor(s):

- (1) Dr. S. Srinivasa Rao, V. R. Siddhartha Engineering College, India.
- (2) Dr. Aurora Martínez Romero, Juarez University, Mexico.
- (3) Dr. Ana Cláudia Coelho, University of Trás-os-Montes and Alto Douro, Portugal.

Reviewers:

- (1) Esmail Mortaz, Shahid Beheshti Medical University, Iran.
 - (2) B. Gomathi, Deemed to be University, India.
 - (3) Andrés Joaquín Guarnizo Chávez, Universidad de Cuenca, Ecuador.
- Complete Peer review History: <https://www.sdiarticle4.com/review-history/69563>

Mini-review Article

Received 01 June 2021
Accepted 21 July 2021
Published 22 July 2021

ABSTRACT

Ever since the human race has been exposed to the novel COVID 19 illness, newer and newer intriguing features of the COVID viral plethora are seen with each passing day. Many manifestations of the COVID 19 illness have been baffling and unexplainable to researchers currently. One such unusual presentation seen is 'happy hypoxia' or silent hypoxemia in a third of patients' total number. This review article is intending to put some light on the puzzling condition of happy hypoxia. We authors refer you through various theories postulated for happy hypoxia. It has definite clinical implications in the sense that it can be lifesaving if detected early and promptly in a COVID patient. We conclude that happy hypoxia or silent hypoxemia is a new entity and should be diagnosed with a high index of suspicion in COVID suspect patients in both young patients with no co morbidities and the elderly and diabetics. Diagnostic modalities like pulse oximeter should be widely used at hospitals and clinics and for self-monitoring by the patients at homes. Also, chest X-rays or HRCT imaging of the lungs is essential in the early stages to identify the early infective changes with compromised lung function and rule out this happy hypoxia. Also, further research is essential to find the exact ethologic of this subclinical though ominous prognostic entity.

Keywords: Happy hypoxia; silent hypoxemia; COVID 19; hypoxemia; HRCT; diabetics.

*Corresponding author: E-mail: hod.medicine@smcw.siu.edu.in;

1. INTRODUCTION

COVID-19, the disease caused by SARS CoV19 virus, has infected millions globally. It is a novel coronavirus with not much knowledge to clinicians and researchers. The disease varies from a short asymptomatic illness to a rapidly deteriorating fatal course or lingering symptoms of myalgia and weakness over many days. Many atypical patterns and findings are seen with this novel, notorious and potentially fatal COVID illness [1].

One such unusual presentation seen is 'happy hypoxia', or silent hypoxemia. In happy hypoxia, oxygen levels of the patient, become low. Still, the paradox is that the patient is unaware of it and may not complain of shortness of breath or any other complaint. The exact cause of such a condition is not yet proven, but many experts have put up their theories in this regard. The degree of hypoxemia and the patients' symptoms are mismatched in COVID 19, but very little is known about the lung hemodynamic and its path physiology. The normal saturation [2] of oxygen in the blood is 95 to 99%. Any level is lower than 94% can compromise lung oxygenation and hemodynamic. This is seen with any acute lung pathologies like pneumonia and can cause the patient to be breathless, called hypoxic (tissues) due to hypoxemia (blood).

1.1 Objective

The role of happy hypoxia in COVID-19 infected patients.

2. LITERATURE SURVEY

The various theories postulated are:

- Shortness of breath is subjective and complained by the patient, so a clinician may not diagnose it unless the patient complains, which he may not, due to various reasons like a good lung reserve.
- Fever or inflammation may alter the body's response to hypoxia: The chemo receptors in carotid bodies respond only to PaO₂ alone and not to the SaO₂. But there can be variation with temperatures [3].
- There is an increased brain sensitivity to low carbon dioxide CO₂ levels, but it is absent for oxygen levels in the blood in a hypoxic state. There can be mild changes in ventilation only when PaO₂ begins to drop to less than 60 mmHg; this is only half

of the patients. But if the PaO₂ levels fall with an increase in carbon dioxide, the changes are not as dramatic as PaCO₂ [4] changes alone.

- The ox haemoglobin dissociation curve may shift to the left because of the result of respiratory alkalosis (drop-in PaCO₂), which is due to tachypnoea and hyperpnoea as a result of hypoxemia. During low PaCO₂ periods, there is an increased affinity of the haemoglobin [5] for oxygen, and so there is increase in O₂ saturation for PaO₂. Hence SpO₂ is very stable during very low levels of PaO₂. But if the PaO₂ levels fall with an increase in carbon dioxide, the changes are not as dramatic as with PaCO₂ changes alone [6].
- During the early phase of COVID-19, low saturation levels are not always accompanied by obvious respiratory difficulties. As there is a fall in oxygen levels in COVID-19 patients, there is no brain response till the oxygen falls to a minimum. The patient becomes breathless [7] at this time. Also, as seen in most patients, if there is very less carbon dioxide, it reduces the effect of lowering the oxygen level. So it is suspected to be COVID infection in sensing like the case of the sense of smell.
- Deep breathing may be comfortable even when carbon dioxide levels are in the normal range. Normally as in lung infection and consolidation, the fall in SPO₂ levels is seen along with pulmonary edema and effusion [8] and high CO₂ levels in the lungs. This can cause breathlessness and not the low levels of oxygen in the blood.
- According to recent research, the COVID virus acts by using the ACE2 receptor for entry in cells. The receptors are expressed in multiple organs like the heart, lungs, brain, and intestines. The brain cells, with the carotid bodies involved in sensing breathlessness, possess the ACE2 [9] receptors; hence, they may fail in sensing the hypoxia, which can lead to the phenomenon of happiness hypoxia.
- Another reason could be clotting mechanisms and micro emboli like in cases of pulmonary embolism. It causes an increase in alveolar dead space and alveolar hypoventilation [10] if the minute volume remains unchanged. Impaired alveolar diffusion of oxygen will lead to 'silent hypoxia' and a consistent drop in oxygen saturation. Unlike other diseases,

the body tries to compensate by increasing tidal volume and, to a lesser extent, the respiratory rate in COVID-19 disease. The rise in tidal volume may be achieved by increasing the aspiratory flow and consequently the work of breathing. The patient may be completely unaware of the increased respiratory load, and this is a state called 'happy hypoxia' [11].

- Two conditions can attenuate the feedback of the respiratory system to hypoxia. These are type 2 diabetes mellitus and old age, wherein the response is reduced to half, thus making them candidates for silent hypoxia.
- Also, there is a vast difference in the lungs' respiratory drive and capacities in various patients, which could explain why a limited number of patients have this condition of happy hypoxia.

2.1 Happy Hypoxemia

In COVID-19 patients, the hypoxemia and mild respiratory discomfort has difference in opinion among the physicians who treat the patients in respiratory failure. Guan reported dyspnea in only 18.7% of 1099 hospitalized COVID-19 patients, despite low PaO₂/FiO₂ ratios, abnormal CT scans (86%) and common requirement for supplemental oxygen (41%). Happy or silent hypoxemia is not exclusively seen in COVID-19, but may also occur in patients with atelectasis, intrapulmonary shunt (i.e. arterio-venous malformations) or right-to-left intracardiac shunt. The adequacy of gas exchange is primarily determined by the balance between pulmonary ventilation and capillary blood flow, referred to as ventilation/perfusion (V/Q) matching. In the initial phase of COVID-19, several mechanisms contribute to the development of arterial hypoxemia, without a concomitant increase in work of breathing. Rapid clinical deterioration may occur.

3. PROPOSED METHODOLOGIES

In a study of COVID-19 disease, only 19% had breathlessness; 62% of severe COVID disease and 46% of intubated, ventilated, and dead patients are present.

A study suggested direct interaction by COVID with the heme moiety of haemoglobin. It was postulated that the heme levels in serum increase in COVID illness and act with dangerous iron ions (Fe³⁺), leading to inflammatory reactions and

death of the cell [12] (ferroptosis). Hence serum ferritin is produced in large amounts, which bind these free ions to minimize tissue damage.

A study suggests that minimal thrombotic episodes may start forming in the lungs in the early stages of the disease due to inflammatory [13] reactions in their blood vasculature, starting the blood's clotting mechanism, thus restricting lungs from getting the required oxygen.

This scenario may be like the setting of COVID pneumonia [14] of Type L, with low elasticity but normal lung compliance. The other presentation is seen as Acute Respiratory Distress Syndrome (ARDS), a Type H phenotype. As opposed to this, [15] have presented a group of patients with early intubation in the COVID course. This group had reduced compliance and a standard presentation in concordance with the Berlin criteria for ARDS [9].

Breathing has a central control by the medullar and centres of respiration of the midbrain (Fig. 1), which monitors the 'respiratory drive' to coordinate breathing with the other systems' varying demands. Also, breathing is affected by multiple sensory, pain, and mental affective stimuli via the cerebrum and hypothalamus's cortex.

4. RESULTS AND DISCUSSION

The key role of the respiratory drive is played by the chemo receptors, both central and peripheral. The difference in the carbon dioxide pressure is dissolved in the blood as PaCO₂ is the most important determinant, which can act by shifts in pH at both the peripheral and central chemo receptors [1].

A report by Guan showed only 18.7% of 1099 hospitalized COVID-19 patients had dyspnoea despite low PaO₂/FiO₂ ratios, common requirements for supplemental oxygen (41%), and abnormal CT scans (86%), the Happy/silent hypoxemia is not only seen in COVID-19 infected diseases but also seen in patients with the intrapulmonary shunt (i.e., arteriovenous malformations), a telecast is or right-to-left intracardiac shunt. The difference primarily decides the requisite gas exchange between the lung ventilation and capillary blood perfusion, commonly known as the ventilation-perfusion (V/Q) matching. Intrapulmonary shunting, loss of lung perfusion regulation, intravascular micro thrombi can lead to COVID-19 with hypoxemia.

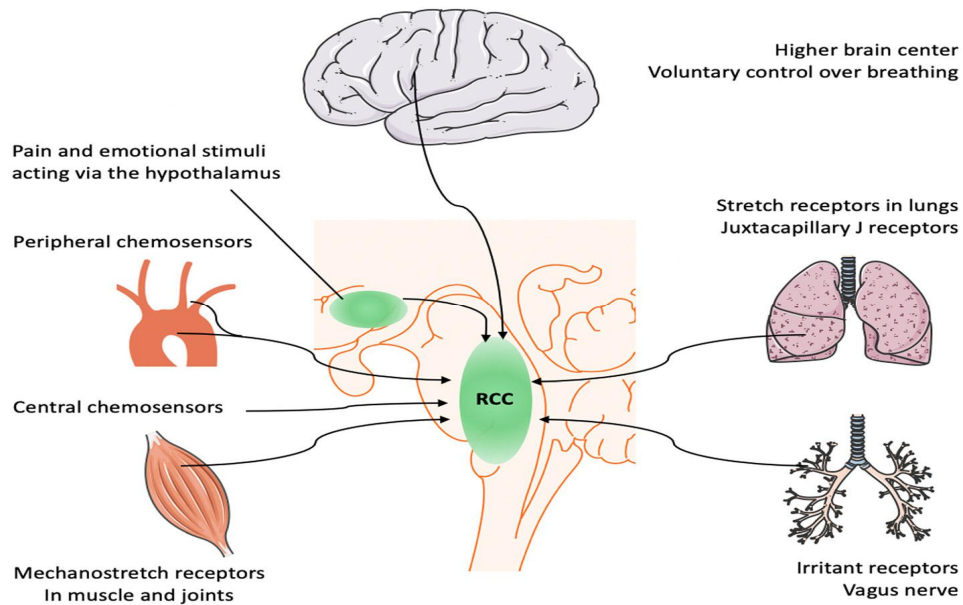


Fig. 1. Respiratory research (2020) 21:198

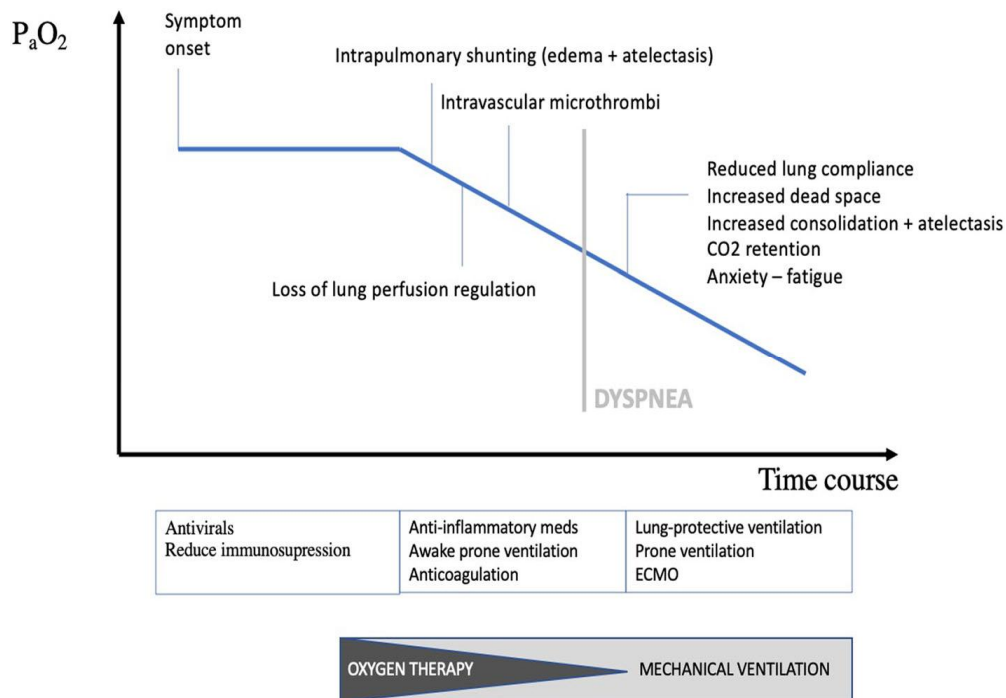


Fig. 2. Mechanical ventilation (2020) 21:198

4.1 Clinical Implications

- Happy hypoxia is a harbinger of a morbid and downhill course of illness with oxygen therapy using mechanical ventilation, as shown in Fig. 2, so increased awareness and early identification of cases to avoid serious complications of COVID.
- The symptoms include lung perfusion loss, anticoagulation, and anti-inflammatory process in the body.

- The loss of the immune system, loss of dead space with lung compliance, CO₂ retention anxiety, and fatigue.
- The sense of smell loss, anxiety, loss of hope, loss of sleep leading to hypoxia, and suppression of oxygen level are the common symptoms that the patients of COVID-19 infections face.
- As shown in Fig. 2, it relies on diagnostic methods like pulse oximeter and imaging to screen patients than clinically diagnosing the hypoxia.

5. CONCLUSIONS

Happy hypoxia or silent hypoxemia is a new entity. It should be diagnosed with a high index of suspicion in COVID-19 suspects the patients, especially the young patients with no comorbidities. There are elderly and diabetic patients who also suffer from hypoxemia. It leads to many health diseases that affect cardiac and breathing problems. Diagnostic modalities like pulse oximeter should be used widely at hospitals and clinics, but self-monitoring of the hypoxemia patients should be done at home. So the increased awareness and early identification of cases are necessary to avoid the serious complications of COVID.

The symptoms include lung perfusion loss, anticoagulation, and anti-inflammatory process in the body. The effects of fatal COVID disease infection lead to a lower immune system, the loss of dead space with lung compliance, CO₂ retention in the lung is reduced, anxiety and fatigue. The sense of smell loss, anxiety, loss of hope, loss of sleep leading to hypoxia, and suppression of oxygen level are the common symptoms that the patients of COVID-19 infections face. Chest Xray or HRCT imaging of the lungs is required in the early stages to identify the lung function complications with any novel disease of COVID 19. Much of the research is needed to find the exact ethologic of this subclinical though ominous prognostic entity.

CONSENT

It is not applicable.

ETHICAL APPROVAL

Ethical approval has been taken from Symbiosis International (Deemed University), Pune, Maharashtra, India.

COMPETING INTERESTS

Authors have declared that no competing interests exist.

REFERENCES

1. Dhont S, Derom E, Van Braeckel E, Depuydt P, Lambrecht BN. The pathophysiology of 'happy' hypoxemia in COVID-19. *Respiratory Research*. 2020; 21(1):1-9.
2. González-Duarte A, Norcliffe-Kaufmann L. Is 'happy hypoxia' in COVID-19 a disorder of autonomic interoception? A hypothesis. *Clinical Autonomic Research*. 2020;30(4): 331-3.
3. Happy hypoxia in COVID-19: New study may have found possible causes behind this biology-defying complication.
4. Couzin-Frankel J. The mystery of the pandemic's 'happy hypoxia'.
5. Chaudhuri S, Shanbhag V, Nileshwar A. "Happy hypoxia" of COVID-19: Are we happy with our oxygen reserves?. *Indian Journal of Respiratory Care*. 2020; 9(2):131.
6. Tabin M, Sharma P. Penetrating missile injury by sudden oxygen release from compressed oxygen cylinder: a case report. *Journal of Indian Academy of Forensic Medicine*. 2013;35(4):392-7.
7. Tobin MJ, Laghi F, Jubran A. Why COVID-19 silent hypoxemia is baffling to physicians. *American Journal of Respiratory and Critical Care Medicine*. 2020;202(3):356-60.
8. Sridharan S, Varghese R, Venkatraj V, Datta A. Hypoxia stress response pathways: Modeling and targeted therapy. *IEEE Journal of Biomedical and Health Informatics*. 2016;21(3):875-85.
9. Wilkerson RG, Adler JD, Shah NG, Brown R. Silent hypoxia: a harbinger of clinical deterioration in patients with COVID-19. *The American Journal of Emergency Medicine*. 2020;38(10):2243-e5.
10. Acharya S, Rajasekar A, Shender BS, Hrebien L, Kam M. Real-time hypoxia prediction using decision fusion. *IEEE journal of biomedical and health informatics*. 2016;21(3):696-707.
11. Harada H. Hypoxia-inducible factor 1-mediated characteristic features of cancer cells for tumorradioreistance. *Journal of radiation research*. 2016;57(S1):i99-105.

12. Pandey A, Prakash G. Deduplication with Attribute Based Encryption in E-Health Care Systems. *International Journal of MC Square Scientific Research*. 2019;11(4): 16-24.
13. Romero D, Jané R. Global and Transient Effects of Intermittent Hypoxia on Heart Rate Variability Markers: Evaluation Using an Obstructive Sleep Apnea Model. *IEEE Access*. 2021;9:19043-52.
14. Bajwa N, Sung S, Ennis DB, Fishbein MC, Nowroozi BN, Ruan D, Maccabi A, Alger J, John MA, Grundfest WS, Taylor ZD. Terahertz imaging of cutaneous edema: correlation with magnetic resonance imaging in burn wounds. *IEEE Transactions on Biomedical Engineering*. 2017;64(11):2682-94.
15. Deepak KS, Sivaswamy J. Automatic assessment of macular edema from color retinal images. *IEEE Transactions on medical imaging*. 2011;31(3):766-76.

© 2021 *Bansode and Bansode*; This is an Open Access article distributed under the terms of the Creative Commons Attribution License (<http://creativecommons.org/licenses/by/4.0>), which permits unrestricted use, distribution, and reproduction in any medium, provided the original work is properly cited.

Peer-review history:
The peer review history for this paper can be accessed here:
<https://www.sdiarticle4.com/review-history/69563>