

FREEMAN-SHELDON SYNDROME: A CASE REPORT

Salehpour SH. MD, MPH¹
Saket S. MD²

1. Pediatric Endocrinologist,
Department of Pediatric
Endocrinology and Metabolic
diseases ,Genomic Research
Center, Shahid Beheshti University
of Medical Sciences, Tehran, Iran
2. Assistant Professor of Pediatrics,
Madani Children's Hospital. Lorestan
University of Medical Sciences and
Health Services, Khorram Abad, Iran

Corresponding Author:
Salehpour SH. MD, MPH
email: shadabshadab@yahoo.com

Received:7-May-2008
Last Revised:10-Mar-2009
Accepted:4-June-2009

Abstract

Objective

The Freeman-Sheldon syndrome is a rare congenital myopathy and dysplasia, in which fibrotic contractures of the facial muscles result in the characteristic “whistling face”. Difficulties with intubation may be attributed in part to microstomia and micrognathia. In addition to other deformities, limb myopathy results in ulnar flexion contractures of the hand and equinovarus/valgus deformities of the feet. Intravenous access may be difficult because of limb deformities and thickened subcutaneous tissues. Limbs may be encased in plaster casts or splints limiting the available sites for venepuncture. The authors report with a review of literature the case of an infant with Freeman-Sheldon syndrome, which his characteristics was mentioned above.

Keywords: Genetic factors, Freeman-Sheldon syndrome, craniofacial dysostosis, whistling face Syndrome

Introduction

Freeman-Sheldon syndrome(1) is a rare inherited autosomal dominant disorder (gene mapped on chromosome 11p15.5) characterized by multiple body contractures (restricted movement around two or more body areas) at birth (congenital), abnormalities of the head and face (craniofacial) area, defects of the hands and feet, and skeletal malformations. Craniofacial abnormalities may consist of characteristic facial features that make the individual appear to be whistling. These features include an extremely small puckered mouth (microstomia), a “full” forehead appearance, unusually prominent cheeks, and thin, pursed lips. Affected infants may also have an unusually flat middle portion of the face, a high roof of the mouth (palate), an unusually small jaw (micrognathia), an abnormally small tongue (microglossia), and/or a raised, scar-like mark in the shape of an “H” or a “V”, extending from the lower lip to the chin. Freeman-Sheldon syndrome can be inherited as an autosomal dominant genetic trait. However, most cases occur randomly with no apparent cause (sporadically).

Case history

A male infant, aged 17 months, with club feet was scheduled for surgery under general anaesthesia. This infant was born to a 27-year-old healthy gravid 2, para 2, Iranian mother. He had unrelated normal parents and a 7-year-old healthy sister. An ultrasound examination was performed, confirming polyhydramnios with a deformity of the both feet and hands of the fetus. Following onset of spontaneous labor, the infant was born at term, by normal vaginal delivery, with a birth weight

of 3.2kg. Despite chromosomal analysis being normal (46,XY) and there being no family history of congenital disease, the dysmorphic features of infant suggested a diagnosis of the Freeman-Sheldon syndrome.

At eight weeks of age, the infant was referred to the surgery and neurology clinics of the Mofid Children's hospital for micrognathia (small jaw) and evaluation of an abnormally high palate. Physical examination revealed a 3.78 kg infant with dysmorphic features affecting the face and all four extremities. The eyes were deeply set below a broad ridge of supraorbital soft tissue with hypertelorism, blepharophimosis and epicanthic folds. A high arched palate and a small tongue were also observed. The combination of microstomia, micrognathia and a fixed facial expression (Figures 1 - 3) presented the characteristic "whistling face." The pathognomonic chin mound was present and the neck was short. Intermittent partial upper airway obstruction was characterized by noisy breathing, tracheal tugging, intercostal recession and pectus excavatum. Although there was a history of difficulty with swallowing and intermittent choking, the chest was clear to auscultation. Cardiovascular examination and the genitalia were normal. All four limbs were hyperreflexic, without evidence of weakness. Distal limb abnormalities were present with fixed ulnar deviation and dorsi-flexion of both wrists, fixed flexion of the third and fourth digits on both hands at the proximal interphalangeal joints (Figures 2,4), left foot calcaneovalgus and severe rigid equinovarus of the right foot. Results of the preoperative laboratory investigations were unremarkable. Echocardiography was also normal. Radiology of the skull demonstrated craniofacial disproportion.

At 17th months of age, the infant was referred to Endocrinology and Metabolic diseases clinic of our hospital for evaluation of his risk for surgery of club feet under general anaesthesia. Physical examination revealed an 8.2 kg infant with the characteristics mentioned above.

Discussion

Since its original description in 1938(2), Freeman-Sheldon syndrome has also been variously described as the Windmill-Vane-Hand syndrome(3), Whistling

face-windmill Vane-Hand syndrome, Distal arthrogyriposis type 2A, cranio-carpo-tarsal dysplasia and the whistling face syndrome(4). This syndrome is characterized by a masklike face with a small pursed mouth, or the "whistling face", ulnar deviation of the hand and fingers, talipes equinovarus, deep-set eyes, epicanthus, blepharophimosis, ptosis and strabismus(5-7). Although most cases occur sporadically it is thought to be transmitted by autosomal dominant inheritance (8) and there are at least two case reports of first degree transmission(9-11). Not all cases are equally affected and there exists a spectrum of deformity and disability. Affected infants often have abnormalities affecting the eyes, including widely-spaced deep-set eyes, crossed eyes (strabismus), and/or down slanting eyelid folds (palpebral fissures). Malformations of the hands and feet are also characteristic of Freeman-Sheldon syndrome. Children with Freeman-Sheldon syndrome may also exhibit speech impairment, swallowing and eating difficulties, vomiting, failure to grow and gain weight at the expected rate (failure to thrive) and/or respiratory problems that may result in life-threatening complications. The precise mechanism of this combined skeletal and muscular dysplasia is unclear, although Sauk et al(9) suggest that hypoplasia of the muscle bundles supplied by the motor branch of major nerves may cause these abnormalities. Biopsy of the affected muscles reveals fibrosis which may contribute to the contractures.

In conclusion, difficulties with the airway, intubation and intravenous access may complicate the course of anaesthesia in patients with the Freeman-Sheldon syndrome, making it necessary for the anaesthetist to be aware of the problems associated with this syndrome.

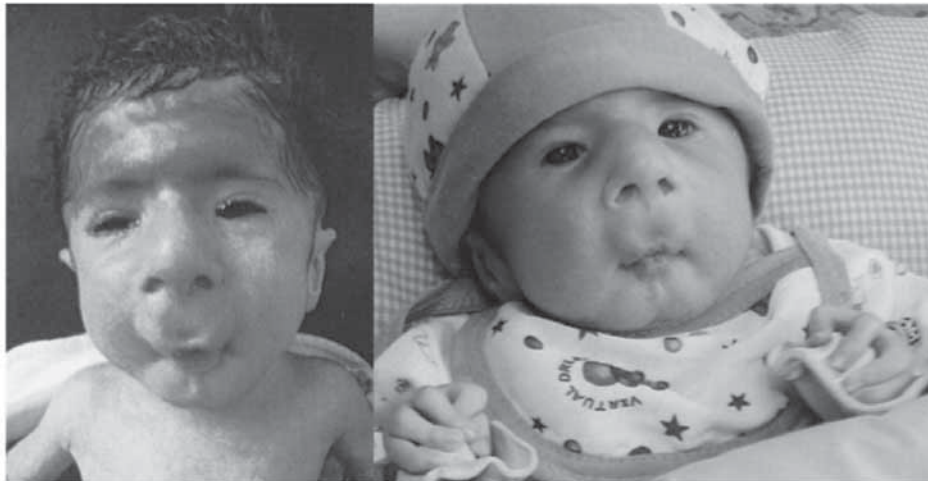

Fig 1,2: Frontal photograph of patient, showing microstomia and hypertelorism.

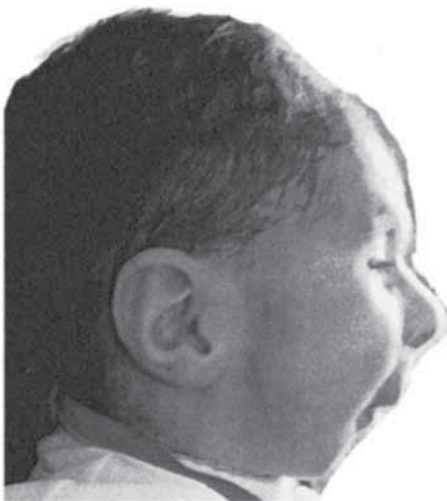

Fig 3: Lateral photograph of patient, showing micrognathia.

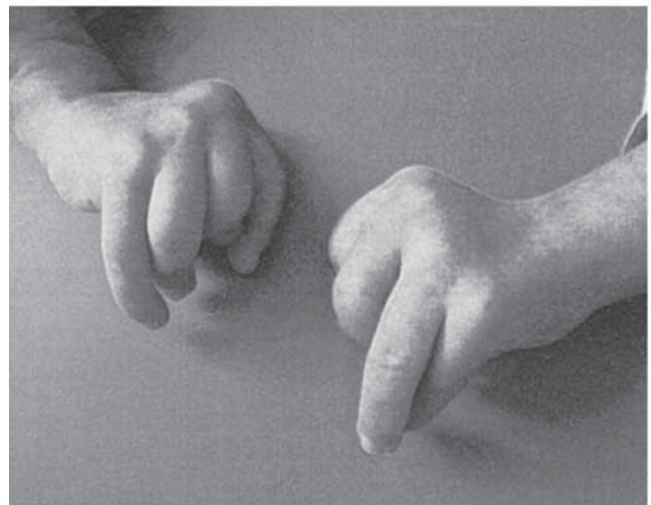


Fig 4: fixed ulnar deviation and dorsiflexion of both wrists, fixed flexion of the third and fourth digits on both hands at the proximal interphalangeal joints.

References

1. Freeman EA, Sheldon JH. Cranio-carpo-tarsal dystrophy. *Arch Dis Child* 1938; 13: 277-83.
2. Kenneth L Jones. *Smith's Recognizable Patterns of Human Malformation*. 5th ed. Philadelphia: WB Saunders Co; 1997. P. 214-215.
3. Sauk JJ, Delaney JR, Reaume C, Brandjord R, Witkop CJ. Electromyography of the oral-facial musculature in craniocarpal tarsal dysplasia (Freeman-Sheldon syndrome). *Clin Genet* 1974; 6:132-7.
4. Fraser FC, Pashayan H, Kadish ME. Cranio-carpodysplasia - report of a case in father and son. *JAMA* 1970; 211:1374-6.
5. Malkawi H, Tarawneh M. The whistling face syndrome, or craniocarpotarsal dysplasia. Report of two cases in a father and son and review of the literature. *J Pediatr Ortho* 1983;3: 364-9.
6. Walker BA. Whistling face, Windmill-Vane-Hand syndrome, (cranio-carpo-tarsal dystrophy; Freeman-Sheldon syndrome). *Birth defects. Original article series. The National Foundation* 1969;5(2):228-30.
7. Weinstein S, Gorlin RJ. Cranio-carpo-tarsal dysplasia or the whistling face syndrome, I: clinical considerations. *Am J Dis Child* 1969; 117:427-33.
8. Behrman RE, Kliegman RM, Jenson HB. *Nelson Textbook of Pediatrics*. 17th ed. Philadelphia: WB Saunders Company; 2004. P.2110.
9. O'Connell DJ, Hall CM. Cranio-carpotarsal dysplasia. A report of 7 cases. *Radiology* 1977;123:719.
10. Millner MM, Mutz ID, Rosenkranz W: Whistling face syndrome. A case report and literature review. *Acta Paediatr. Hung* 1991;31:279.
11. Ferrari D, Bettuzzi C, Donzelli O. Freeman-Sheldon Syndrome A case report and review of the literature. *La Chirurgia degli Organi di Movimento* 2008;92(2):127-131.