



International Journal of Scientific Research in Dental and Medical Sciences

www.ijrdms.com



Dens Invaginatus with Palatal Expansion and Buccal Sinus Tract: A Case Report

Hoda Alimadadi, Hengameh Ashraf, Navid Nasrabadi*

Department of Endodontics, School of Dentistry, Shahid Beheshti University of Medical Sciences, Tehran, Iran

ARTICLE INFO

Article history:

Received 09 August 2019

Received in revised form 17 September 2019

Accepted 21 September 2019

Available online 30 September 2019

Keywords:

Dens invaginatus

Dens in Dente

lateral incisor

CBCT

ABSTRACT

Dens in dente are a growth disorder caused by the inversion of the coronary tissue into the pulp chamber before mineralization. It can be constrained to the crown or extend the root and influence the periapical area.

The condition seen in the radiographic image is usually like a tooth within a tooth. Although it happens rarely, it is the most frequent malformation detected in human dentition. It can be specially observed in maxillary lateral and then central incisors. Because of the complexity as well as strange anatomy, the tooth has the potential to reveal pulp necrosis and open apex, which may bring about some challenges to manage it. Early detection of the malformation is critical for better handling and makes treatment plans more conservative, like restorative procedures.

We described the management of an uncommon case of type III dens in dente diagnosed using a cone-beam CT scan in a maxillary lateral incisor. The patient had a chronic periapical lesion, a buccal sinus tract, and palatal expansion, which were healed successfully after treating with non-surgical root canal procedure.

1. Introduction

Dens in dente is a rare human tooth malformation which Ploquet first reported in 1794 in whale's teeth, while, later a dentist called 'Socrates' described it in 1856 in human dentition.^[1] This condition seems to happen when the wrapping of the crown surface occurs before calcification, resulting in morphology variation during tooth development.^[2] Before 1918 it was assumed that this abnormality described as dens in dente was a fusion of two teeth; however, according to Moral, it only included a single tooth. An extension which projects from the inner part of the tooth up to the apex is similar to a reverse tooth. Moreover, Moral also found out that the space inside the tooth did not form an interior pulp chamber. Still, it was instead a space that had been previously filled with enamel epithelium. In contrast, the tooth's real pulp chamber would be indicated through the thin fracture-like cleft between the exterior and interior dentinal walls. Nowadays this anomaly is considered as dens invaginatus, tooth inclusion, invaginated odontome, dilated composite odontome, as well as dilated gestant odontome. At the same time, various etiologies at a range of the pressure pout on the dental arch due to the growth, leading to buckling of the enamel organ to infection and trauma, have been proposed for it.^[3] This complication can be experienced in deciduous, permanent, or supernumerary tooth, and a prevalence rate of 0.04% to 10% has been reported.^[4] Also, it appears in males more than females, with a ratio of 3:1. However, it can probably affect any maxillary or mandibular teeth. In contrast, its occurrence in the maxillary lateral incisors is more probable, after which permanent central incisors, premolars, canines, or molars may be affected.^[5, 6, 7, 8] Oehlers^[9] categorized dens invaginatus in three classes considering, how profound the impact had been and how much connection has taken place with the periodontal ligament or periapical tissue. In type 1, an enamel-lined cavity

that is limited to the crown and has not extended outside the cement enamel junction (CEJ) can be observed.^[9] Type 2 represents a hollow space lined by enamel extension to the root, while the connection with pulp may also be possible.^[9] Invagination in type 3 occurs as perforating at the root surface, forming the second apex in the periodontium.^[9] Moreover, patients generally do not know about this malformation, and it is discovered accidentally through an intraoral periapical radiograph (IOPA) that was taken for any other indication.

Usually, it looks like a loop-resembling or pear-like deficiency lined by an opaque radio line having an equivalent mass to the enamel density, which makes a view of a tooth inside another tooth.^[10, 11] However, histologic inspection indicates that the dentin under the invagination could remain intact with no abnormalities, or can include strains of underlying connecting tissue or even delicate canals connected to the dental pulp, or dentin with a hypomineralized as well as irregular configuration. The composition and density of the enamel lining the invagination can be variable as well. The invagination causes accumulation of irritants in space, disconnected from the pulpal tissue through a narrow substrate of enamel and dentin, and reflects vulnerability for caries progression.

From a clinical perspective, the affected tooth can appear normal or possess a bigger mesiodistal size of the cervical third than the incisal third. sometimes it can appear with a bigger crown and a notable cingulum with a central foramen or bifid cingulum; in some cases, a conical crown may also be reported.^[12, 13, 14, 15, 16]

Addressing dens invaginatus is almost always a challenging procedure due to its complicated anatomy, and selection of the treatment is usually according to its severity.^[17, 18, 19, 20, 21, 22, 23]

* Corresponding author. Navid Nasrabadi

E-mail address: navid.nasr70@gmail.com

Department of Endodontics, School of Dentistry, Shahid Beheshti University of Medical Sciences, Tehran, Iran

http://doi.org/ 10.30485/ijrdms.2019.197269.1013

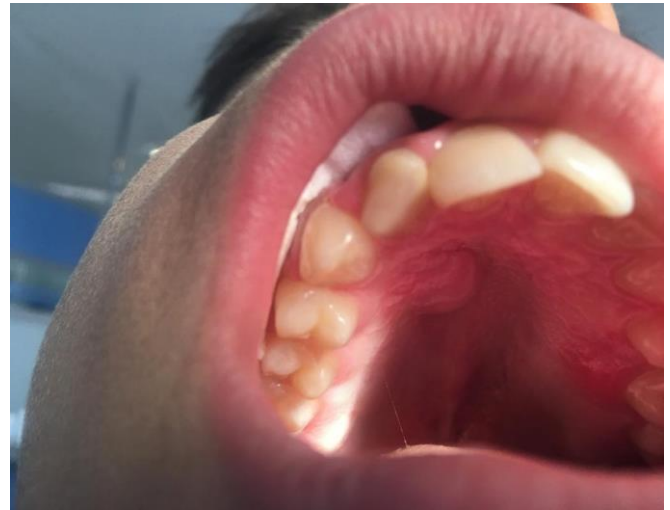Prophylactic treatment would be possible if the problem is diagnosed at early stages, through which the opening of the crown will be sealed with restoratives which have preventive effects on the decay of the invagination and subsequent impacts on the pulp of the major root, particularly in Oehlers instances of type I as well as type II.^[12, 14, 18, 19, 21, 22, 24]

Failure in early identification of this complication can result in invaginated pulp necrosis and periapical lesion. In such conditions, endodontic treatment of the invagination and the major canal can be helpful considering the type of invagination.^[12, 14, 18]

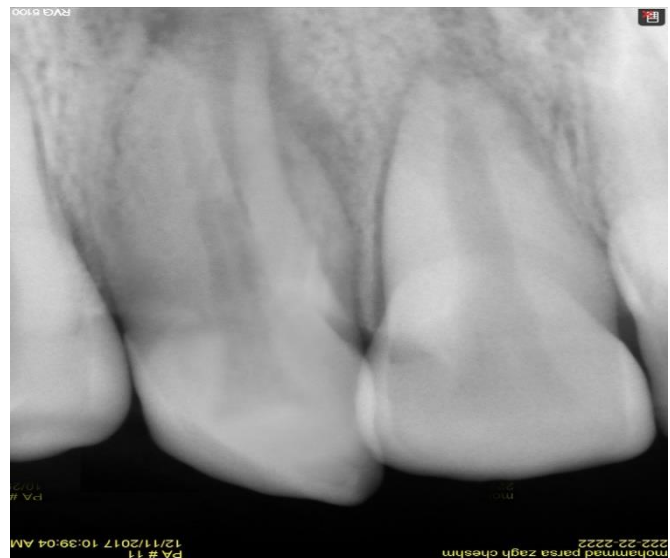
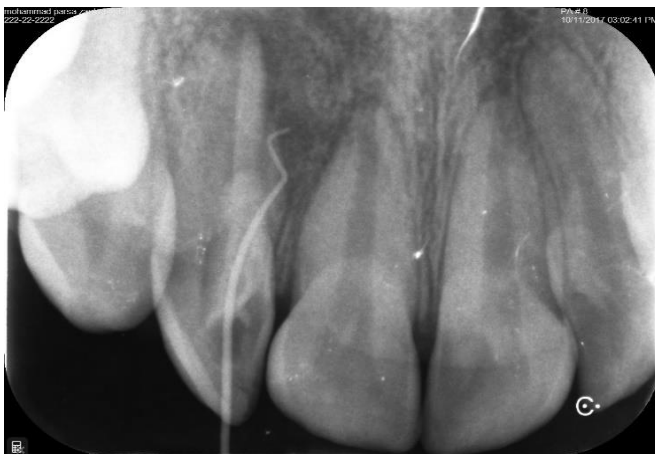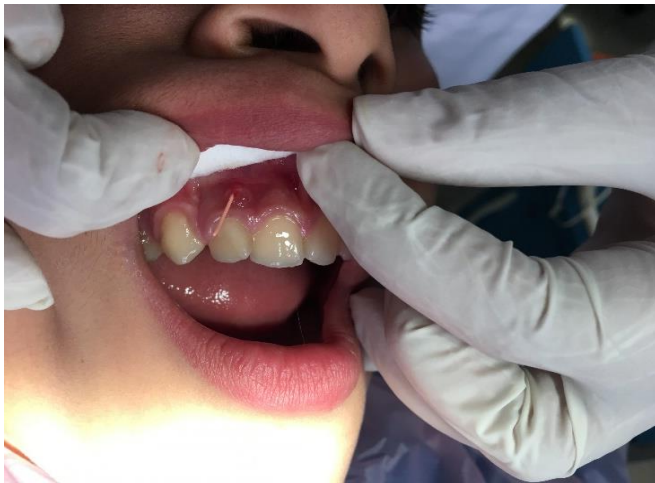It is assumed that dens in dente are related to several abnormal conditions, including taurodontism, microdontia, duplication, supernumerary tooth, and dentinogenesis imperfecta.^[6] Association of dental anomalies and syndromes with DI may present as sensorineural hearing loss syndrome,^[25] cranial suture syndromes,^[26] microdontia,^[27] and mesiodens.^[28] The following case is an example of the management of an uncommon case of dens in dente in a maxillary lateral incisor related to a chronic periapical lesion, buccal sinus tract, and palatal expansion.

2. Case presentation

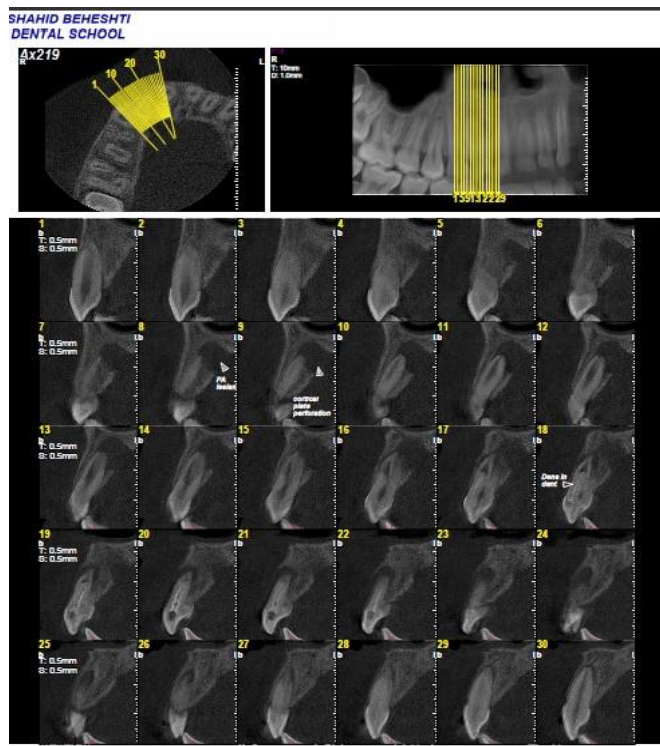
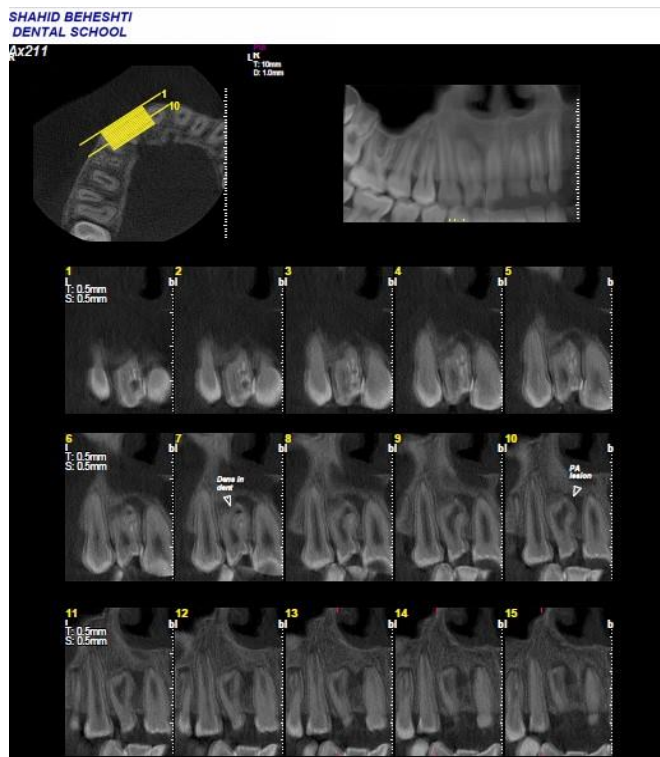
A 12-year-old boy was referred to the outpatient department of endodontics, with the chief complaint of abscess formation in the upper left lateral incisor for the last 6 months. It was somewhat sensitive to pressure. No contribution of the family or medical histories could be found. The patient's dental history revealed that the sinus would heal spontaneously, but reappear in a few days. The extra-oral inspection did not bring any significant results. Based on intraoral clinical inspections, the sinus tract was present in the periapical space of the upper left central incisor (Figure 1a, 1b) with slight inflammation and the expansion in the palatal side. (Figure 2).



Moreover, the tooth showed sensitivity to vertical as well as horizontal percussion. No horizontal or vertical mobility could be observed. In addition, the affected tooth was periodontally healthy. No symptoms could be observed in the patient, while the necessary test also revealed a negative response to cold test through the application of Endo-Frost cold spray (Roeko; Coltene Whaledent, Langenau, Germany). Both the visual v radiographic examination did not reveal an abnormality on the contralateral tooth. After a complete examination of the IOPA radiograph, an identical tooth-like structure, resembling the typical appearance of dens in dente, was found in the root area close to the CEJ. (Figure 3).

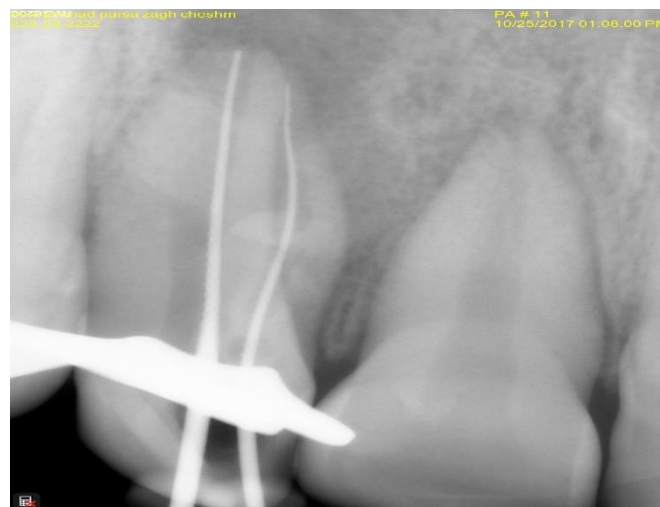


Based on these peculiar clinical and radiological features, a definitive diagnosis of dens in dente was established. The case was discussed in the type III category (Oehler's classification). The case was clinically diagnosed as necrotic pulp with asymptomatic apical periodontitis. A discussion of the anomaly and its prognosis for the patients has been provided along with the plan for root canal treatment. For comprehensive identification of the crown-root morphology, Cone Beam Computerized Tomography (CBCT) was carried out to confirmation type III dens invaginatus diagnosis. (Figure 4a, 4b).

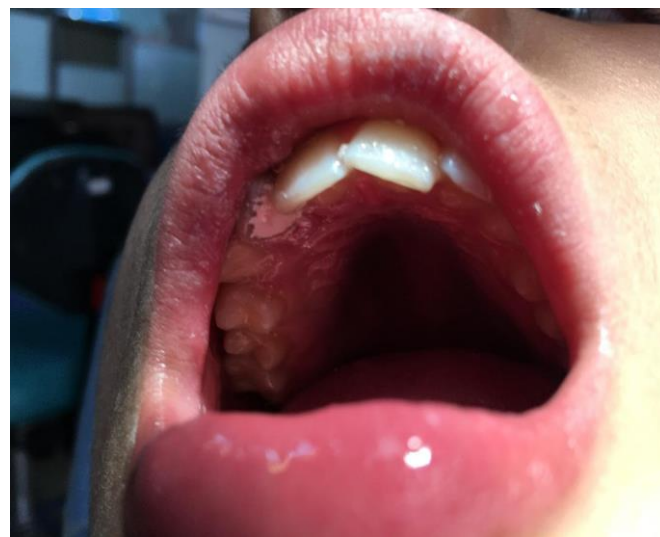

Local anesthesia was performed before the access cavity was prepared using a long-tapered fissure bur in the center of the palatal surface. Ultimately the apical foramen could be accessed. Other walls of the tooth configuration were sound, although it was narrow, and no openings could be observed. Removal of the necrotic pulp was then carried out, and 5% sodium hypochlorite was used for irrigation. Two openings were revealed through access preparation, one related to the central canal, and the other associated with the invagination.

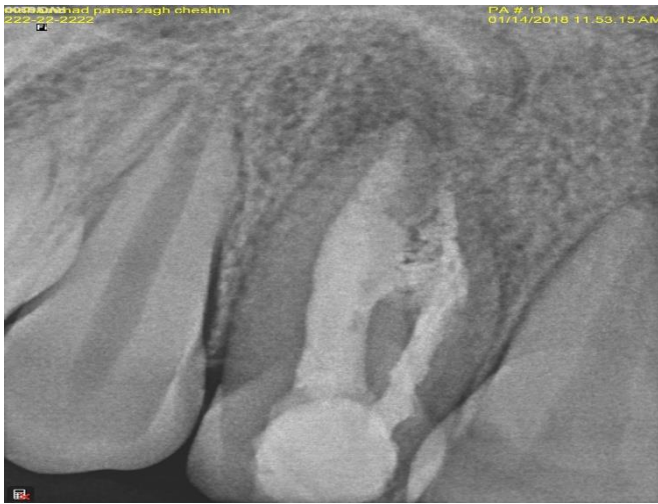For the rest of progress, the working length (Figure 5) was established and then instrumentation of the root canal was accomplished using ISO-size 80 K-file (Dentsply Maillefer, Ballaigues, Switzerland) and ProTaper Universal Rotary Files (Dentsply Sirona, Ballaigues, Switzerland) and irrigated with copious 5% sodium hypochlorite (NaOCl) and indirect passive ultrasonic activation technique (Satelec P5 Newtron[®] ultrasonic, Acteon, France) at the low power with ISO-size 15 K-file for 5 min in two cycles.



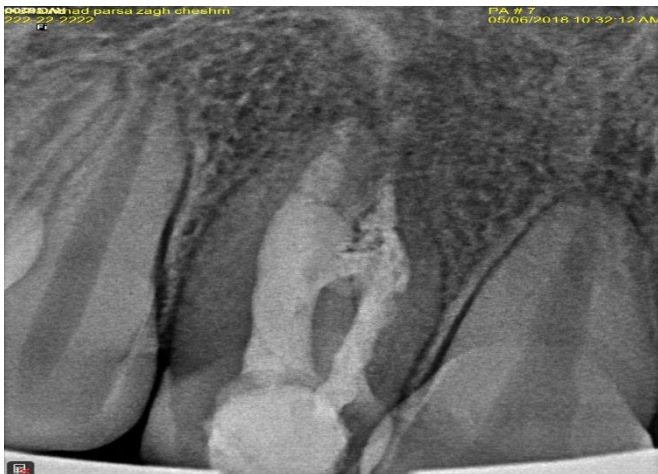Then the canals were dried using sterile paper points. Calcium hydroxide was an intracanal medicament for two weeks (Meta Biomed Co., Ltd., South Korea). Subsequently Cavit (ESPE, Seefeld, Germany) was applied to fill the access cavity (Figure 6) temporarily.



After the two weeks, the tooth did not show any symptoms and was ready for obturation. Cleaning of the canals was performed using K-file with copious 5% NaOCl solution to flush out the calcium hydroxide in the next appointment. Finally, the canals were rinsed with 17% ethylenediaminetetraacetic acid (EDTA) and subsequently, 2.5% NaOCl, and dried using sterile paper points. The central canal was obturated using a cold lateral technique for the apical third. The remaining part of the canal was refilled with thermoplasticized gutta-percha employing the Obtura III MAX system (Obtura Spartan, Algonquin, IL, USA) and AH26 sealer (Dentsply Maillefer, USA). The invagination route just obtured by Obtura III MAX system. (Figure 7).



One-month follow-up indicated no symptoms for the tooth, and the patient's referral to the department of prosthodontics was recommended for restoration. Restoration of the coronal part was carried out using composite resin (3M™ ESPE™ Filtek™ Z250XT Universal Restorative). The 12-month post-treatment radiograph showed a reduction of the periapical radiolucency without any clinical symptoms. (Figure 8).



3. Discussion

Based on observations dens invaginatus usually influences the maxillary lateral incisors and rarely occurs in the lower jaw. The tooth which has received treatment in the present study was a maxillary lateral incisor. Dens invaginatus generally indicates an extraordinary radiographic view. Several authors have considered dens invaginatus as the most common malformation in human dentition.^[22, 28]

In dens invaginatus a thin layer of dentin separates the invagination region from the pulpal tissues. Communication is often observed with the oral cavity, which can be hypoplastic and may predispose to the entry of irritants and thereby result in necrosis of the pulp along with infection. Treatment is classified from preventive sealing or restoration of invagination to non-surgical root canal therapy, intentional replantation, or extraction.^[10] Conventional and digital radiography renders 3D anatomical structures two-dimensionally with inherent distortions in different planes.

According to Oehler's classification, the case was Type III dens invaginatus, in which the additional canal is palatal to the central canal.^[9] Although the case had a periapical lesion, since the root was well formed and had an apical constriction, the non-surgical root canal treatment approach was chosen. The use of calcium hydroxide reduces bacterial counts and helps the tissues to recover and heal. Healing of the intraoral sinus is also a positive sign showing that the treatment was working efficiently.^[38]

Nerwich *et al.* reported that the derived hydroxyl ions of the calcium hydroxide intracanal dressing need a few hours to diffuse into the interior root dentin, a 1–7-day period to extend to the exterior root dentin, and 2–3-week interval to come to its maximum level.^[39] For teeth with complex anatomy where proper debridement is difficult to achieve as in this case of dens in dente, a good shaping followed by maximum cleaning, optimum irrigant interaction with the root canal dentin, and a perfect coronal seal is the key to achieving a successful treatment outcome. Periodic follow-up of the case at 3, 6, 9, and 12 months also played a significant role in the healing of the periapical lesion. If the lesion's size increased on the follow-up appointments, then a surgical treatment would have been warranted.

The manual or rotary instrument is used independently in such cases, but irrigant agitation is of utmost importance for cleaning the complex canal system of dens invaginatus. The agitation is usually performed by applying sonic or ultrasonic devices on an irrigation solution.

Activation by direct or indirect ultrasonic devices might be more effective in enhancing the cleaning of complex canal morphology than sonic activation regardless of the time.^[29] The irrigation step should include NaOCl from 2.5% to 5.25% or even 6%.^[30] Some case reports recommended using EDTA 17% and NaOCl 2.5% for final irrigation.^[31]

Healing takes place in periapical lesions after sufficient biomechanical debridement along with the root canal system obturation. Several investigators reported healing within the 1st year, while others said that healing could take longer.^[32, 33] In the present case, the size of the periapical lesion was reduced after one year. The cases should be followed for more time.

Cleansing and disinfecting the areas out of reach in the necrotic canal may be more convenient through the application of calcium hydroxide dressing related to frequent irrigation using sodium hypochlorite solutions of a variety of densities.^[12, 34] Many authors have confirmed that the most suitable procedures for filling dens invaginatus are the ones that apply heat-plasticized gutta-percha. They make the filling of abnormalities shown in these teeth easier.^[18, 26, 35]

Principally, the filling procedure employed for the mentioned canal was heated vertical condensation, whose change was because of the unpredicted separation of the invagination. Consequently, it was decided to use lateral condensation associated with vertical condensation to fill the canal.

Teeth experiencing these conditions reveal narrow and vulnerable root walls, usually in the dental arch, for a short period.^[36] However, maintaining the tooth for a longer time as much as possible is of critical importance, particularly in young people, so that space could be maintained until occlusion has been established.^[37]

4. Conclusion

Overall, although it is difficult to treat and maintain dens invaginatus, the case study presented here had a favorable outcome. It was accordingly indicated that non-surgical root canal treatment was a successful therapy for the case with buccal sinus tract and palatal expansion.

Conflict of Interest

The authors declared that there is no conflict of interest.

Acknowledgments

This research received no specific grant from any funding agency in the public, commercial, or not-for-profit sectors.

References

- Schulze C. Developmental abnormalities of the teeth and jaws. Thoma's oral pathology. 6th edn St Louis, MO: Mosby Company, 1970; 96–183.
- Thomas JG. A study of dens in dente. Oral Surg Oral Med Oral Pathol 1974; 38:653–5. 10.1016/0030-4220(74)90099-1.
- Euler 1939 and Atkins 1943.
- Hovland EJ, Block RM. Nonrecognition and subsequent endodontic treatment of dens invaginatus. J Endod 1977; 3:360–2. 10.1016/S0099-2399(77)80067-8.

5. Thomas JG. A study of dens in dente. *Oral Surg Oral Med Oral Pathol* 1974; 38:653–5. doi:10.1016/0030-4220(74)90099-1.
6. Pindborg JJ. Pathology of the dental hard tissues. Copenhagen: Munksgaard, 1970:58–65.
7. Gesteira MFM, Corbacho MM, Vidal SMM, Pastor IMO. Terapia endodôntica em dens invaginatus: relato de um caso. *RCI Med Biol.* 2007; 6(3):360-70.
8. Vier-Pelisser FV, Pelisser A, Recuero LC, S6 MVR, Borba, MG, Figueiredo JAP. Use of cone beam computed tomography in the diagnosis, planning and follow up of a type III dens invaginatus case. *Int Endod J.* 2012; 45(2):198-208. doi: 10.1111/j.1365-2591.2011.01956.
9. Oehlers FA. Dens invaginatus (dilated composite odontome). I. Variations of the invagination process and associated anterior Crown forms. *Oral Surg Oral Med Oral Pathol.* 1957; 10:1204-18.
10. M. Payne and G. T. Craig, "A radicular dens invaginatus," *British Dental Journal*, vol. 169, no. 3-4, pp. 94–95, 1990.
11. A. P. Bhatt and H. M. Dholakia, "A radicular variety of double dens invaginatus," *Oral Surgery Oral Medicine and Oral Pathology*, vol. 39, no. 2, pp. 284–287, 1975.
12. Gharechahi M, Ghoddusi J. A nonsurgical endodontic treatment in open-apex and immature teeth affected by dens invaginatus using a collagen membrane as an apical barrier. *J Am Dent Ass.* 2012; 143(2):144-8.
13. Kaneko, T, Sakaue H, Okiji T, Suda H. Clinical management of dens invaginatus in a maxillary lateral incisor with the aid of conebeam computed tomography: a case report. *Dent Traumatol.* 2011; 27(6):478-83. doi: 10.1111/j.1600-9657.2011.01021.x.
14. Rodekirchen H, Jung M, Ansari F. Dens invaginatus type II: case report with 2-years radiographic follow-up. *Oral Surg Oral Med Oral Pathol Oral Radiol Endod.* 2006; 102(4):e121-5. doi:10.1016/j.tripleo.2005.10.064.
15. Halvacioğlu-Yigit D, Aydemir S. Endodontic treatment of type II dens invaginatus in a maxillary lateral incisor: A case report. *Case Report Dent.* 2012; 2012:4. doi: 10.1155/2012/153503.
16. Bishop K, Alani A. Dens invaginatus. Part 2: clinical, radiographic features and management options. *Int Endod J.* 41(12):1137- 54. doi: 10.1111/j.1365-2591.2008.01469.
17. Kaneko, T, Sakaue H, Okiji T, Suda H. Clinical management of dens invaginatus in a maxillary lateral incisor with the aid of conebeam computed tomography: a case report. *Dent Traumatol.* 2011; 27(6):478-83. doi: 10.1111/j.1600-9657.2011.01021.
18. Paula-Silva FWG, Rocha CT, Flores DSH, Nelson-Filho P, Silva LAB, Queiroz AM. Root canal treatment of an immature dens invaginatus with apical periodontitis: a case report. *J Dent Child.* 2011; 78(1):66-70.
19. Kristoffesen O, Nag OH, Fristad I. Dens invaginatus and treatment options based on a classification system: Report of a type II invagination. *Int Endod J.* 2008; 41(8):702-9. doi: 10.1111/j.1365-2591.2008.01399.
20. Schmitz MS, Montagner F, Flores CB, Morari VH, Quesada GA, Gomes BP. Management of dens invaginatus type I and open apex: report of three cases. *J Endod.* 2010; 36(6):1079-85. doi: 10.1016/j.joen.2010.02.002.
21. Steffen H, Splieth C. Conventional treatment de dens invaginatus in maxillary lateral incisor with sinus tract: one year follow-up. *J Endod.* 2005; 31(2):130-3. doi: 10.1097/01.
22. Bishop K, Alani A. Dens invaginatus. Part 2: clinical, radiographic features and management options. *Int Endod J.* 41(12):1137- 54. doi: 10.1111/j.1365-2591.2008.01469.
23. De Moor R. Dens invaginatus - a challenge in endodontics. *Rev Belge Med Dent.* 2005; 60(1):49-57.
24. Jung M. Endodontic treatment of dens invaginatus type III with three root canals and open apical foramen. *Int Endod J.* 2004; 37(3):205-13. doi: 10.1111/j.0143-2885.2004.00778.
25. Kantaputra PN, Gorlin RJ. Double dens invaginatus of molarized maxillary central incisors, premolarization of maxillary lateral incisors, multituberculum of the mandibular incisors, canines and first premolar, and sensorineural hearing loss. *Clin Dysmorphol* 1992; 1:128-36.
26. De Coster PJ, Mortier G, Marks LA, Martens LC. Cranial suture biology and dental development: Genetic and clinical perspectives. *J Oral Pathol Med* 2007; 36:447-55.
27. Mupparapu M, Singer SR. A review of dens invaginatus (dens in dente) in permanent and primary teeth: Report of a case in a microdentic maxillary lateral incisor. *Quintessence Int* 2006; 37:125-9.
28. Sannomiya EK, Asaumi J, Kishi K, Dalben Gda S. Rare associations of dens invaginatus and mesiodens. *Oral Surg Oral Med Oral Pathol Oral Radiol Endod* 2007; 104:e41-4.
29. Alberdi JC. Non-surgical endodontic treatment of a maxillary lateral incisor with dens invaginatus: A case report. *Endodontic Practice Today* 2013; 7:31-5.
30. Lichota D, Lipski M, Wozniak K, Buczkowska-Radlinska J. Endodontic treatment of a maxillary canine with type 3 dens invaginatus and large periradicular lesion: A case report. *J Endod* 2008; 34:756-8.
31. Nallapati S. Clinical management of a maxillary lateral incisor with vital pulp and type 3 dens invaginatus: A case report. *J Endod* 2004; 30:726-31.
32. Orstavik D. Time-course and risk analyses of the development and healing of chronic apical periodontitis in man. *Int Endod J* 1996; 29:150-5.
33. Sjogren U, Hagglund B, Sundqvist G, Wing K. Factors affecting the long-term results of endodontic treatment. *J Endod* 1990; 16:498-504.
34. Ruprecht A, Sastry KA, Batniji S, Lambourne A. The clinical significance of dental invagination. *J Pedod* 1987; 11:176-81.
35. Rajini MA, Kaiwar A, Meena N, Kumar RA, Shetty A, Naveen DN, et al. Nonsurgical endodontic treatment of type II dens invaginatus. *J Conserv Dent.* 2009; 12(2):73-6. doi: 10.4103/0972-0707.55622.
36. Fayazi S, Bayat-Movared S, White SN. Rapid endodontic management of type II dens invaginatus using an MTA plug: a case report. *Spec Care Dentist.* 2013; 33(2):96-100. doi: 10.1111/j.1754-4505.2012.00300.
37. Patel S. The use of cone beam computed tomography in the conservative management of dens invaginatus: a case report. *Int Endod J.* 2010; 43(8):707-13. doi: 10.1111/j.1365- 2591.2010.01734.
38. Hegde V, Morawala A, Gupta A, Khandwawala N. Dens in dente: A minimally invasive nonsurgical approach!. *J Conserv Dent.* 2016;19(5):487–489. doi:10.4103/0972-0707.190014.
39. Nerwich, Alan & Figdor, David & Messer, Harold. (1993). PH changes in root dentin over a 4-week period following root canal dressing with calcium hydroxide. *Journal of endodontics.* 19. 302-6. doi:10.1016/S0099-2399(06)80461-9.