

Slow Spinal Cord Compression Inducing by Malignant Peripheral Nerve Sheath Tumors in Cotonou

D. Gnonlonfoun¹, C. Adjien¹, J. Nyangui Mapaga¹, L. Hode², G. Goudjinou¹, A. Sowanou¹, R. Domingo¹, P. Gnigone¹, G. Mambila¹, D. Affanou¹, P. H. Kouna Ndouongo³, D. Houinato¹

¹Department of Neurology, National University Hospital Centre, Cotonou, Bénin

²Department of Neurosurgery, National University Hospital Centre, Parakou, Bénin

³Department of Neurology, National University Hospital Centre, Libreville, Gabon

Email: dieudonne.gnonlonfoun@gmail.com

How to cite this paper: Gnonlonfoun, D., Adjien, C., Mapaga, J.N., Hode, L., Goudjinou, G., Sowanou, A., Domingo, R., Gnigone, P., Mambila, G., Affanou, D., Ndouongo, P.H.K. and Houinato, D. (2018) Slow Spinal Cord Compression Inducing by Malignant Peripheral Nerve Sheath Tumors in Cotonou. *Neuroscience & Medicine*, 9, 22-28.

<https://doi.org/10.4236/nm.2018.91004>

Received: November 5, 2017

Accepted: March 20, 2018

Published: March 23, 2018

Copyright © 2018 by authors and Scientific Research Publishing Inc.

This work is licensed under the Creative Commons Attribution International License (CC BY 4.0).

<http://creativecommons.org/licenses/by/4.0/>



Open Access

Abstract

MPNST is a very uncommon malignant type of neoplasm. It is often associated with neurofibromatosis type 1 (von Recklinghausen disease). It involves large anatomical regions, and thus takes on varied clinical presentations. However, bone location of MPNST, particularly in the spinal canal has been poorly described in the literature. We hereby report the case of a 29-year old young man with MPNST in the spinal canal. He presented a slow spinal cord compression confirmed by spinal MRI. MPNST was revealed through histologic and immune histochemical features after tumor resection.

Keywords

Spinal Compression, Malignancy, MPNST, Cotonou

1. Introduction

Malign peripheral Nerve Sheath Tumors (MPNST), as defined per the 2013 WHO classification, are malignant tumors arising from a peripheral nerve, or from a pre-existing benign nerve sheath tumor. They can also occur in a patient with neurofibromatosis (NF-1).

Aside from these conditions, the diagnosis is based on evidence of Schwannian differentiation as revealed by mixed histologic, phenotypic and ultrastructure features. MPNST is a very uncommon malignant type of neoplasm [1]. Despite their scarcity, MPNST cases were found in different regions of the body whether or not associated with neurofibromatosis type 1 (NF1) [1] [2] [3]. Cases

of MPNST were mainly observed in soft tissues [4], less frequently in the bones [5]. Isolated cases were found in the spine and femur. The authors hereby report a case of slow spinal cord compression indicative of a MPNST.

2. Observation

Mr. D. M., aged 29, with no specific medical prior history, was admitted with gradual onset of motor deficit in the lower limbs. Symptoms had been developing for 8 weeks, including back pain upon coughing that radiated around left side of the body to the middle of the chest, then painless intermittent claudication occurred. A week before he was admitted, he experienced motor decline in the pelvic limbs with acute urinary retention requiring consultation in the emergency department. He had neither fever nor cough, and presented no signs of trauma. His examination revealed a generally altered condition with WHO performance indicator estimated at 3/4. The neurological examination highlighted spastic paraparesia with muscle strength rated at 3/5 and a bilateral Babinski sign. Sensitivity disorders such as hypoesthesia upon protopathic touch and the malgesic type of disorders were found with sensitivity up to dermatome T2. He had sharp pain from T2 to T5. Skin smear examination revealed neither brown skin patches nor neurofibromas. Blood test (CBC Normal, CRP negative) and tuberculin skin test were negative. Spinal MRI (**Figure 1** and **Figure 2**) showed a 5 cm tumor mass, low signal intensity on T1 at the level of T2 thoracic vertebra and high signal intensity on T2 with bone marrow involvement. Tumor-induced slow spinal cord compression was diagnosed and laminectomy was taken with tumor resection. The pathological examination of the resected specimen was carried out in Europe and the results were sent back 6 weeks later. Proliferation of monomorphic malignant spindle cell tumors was evidenced, with predominance of hemangiopericytoma structure (**Figure 3**). The morphological and phenotypic profile of this tumor suggested a Malignant Peripheral Nerve Sheath Tumor (MPNST) with glandular differentiation. Extension work up specifically thoracic-abdominal-pelvic CT scan revealed no particularities. The patient passed away with respiratory distress, 1 month after he was discharged, and before getting the histological and immunohistochemical results.

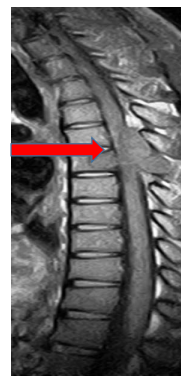


Figure 1. Spinal MRI showing a vertebral body in low signal intensity on T1 at the level of T2 thoracic vertebra.

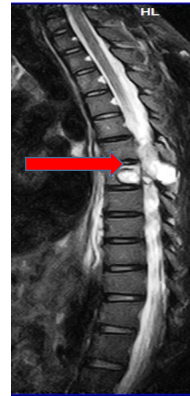

Figure 2. Spinal MRI showing high intensity on T2 at the level of T2 thoracic vertebra with bone marrow involvement.

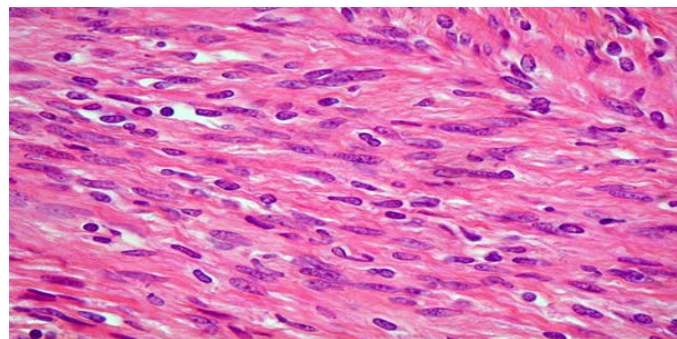


Figure 3. Proliferation of monomorphic malignant spindle cell tumors predominantly of hemangiopericytoma structure.

3. Discussion

MPNST is a nervous system tumor which develops to the detriment of the nerve sheath, resulting from the impairment of derived neural crest and ectoderm cells [6]. It is a rare tumor with an incidence of 0.001% among the general population and 5% - 10% among NF1 patients [7]. It is much higher among NF1 patients because the NF1 gene located on the long arm of chromosome 17 and encoding the neurofibromin protein plays a role in MPNST genesis [8]. MPNST is associated with neurofibromatosis from 2% to 29% of cases [9] [10]. The literature shows that MPNST mainly occurs among young adults of 20 to 50 years of age [11] [12]. There is no gender predominance [8]. Our patient was a 29 years old male. However, pediatric cases were also reported [13] [14]. MPNST clinical signs are not specific. Nonetheless, symptoms often include painless swelling [15] [16]. Our patient presented slow spinal cord compression, with no sign of neurofibromatosis type 1. In the literature, primary intraspinal location is extremely rare [5]. Plexus and large nerves are the preferential locations. NF1 associated with intraosseous MPNST is less prevalent [9] than with soft tissue injuries [17] and thus the absence of neurofibromatosis type 1 in the case of our patient. In fact, neurofibromatosis type 1 diagnosis is clinical in most cases [18]. There is no typical imaging of MPNST [15]. Our patient's MRI helped to deter-

mine the diagnosis of spinal compression through low signal intensity on T1 and high signal intensity on T2 with bone marrow involvement. MRI remains the most advanced examination and provides information on soft tissue injuries [19]. Yet, some authors demonstrated that through MRI, four characteristics could determine MPNST against a neurofibroma diagnosis. They include: size \geq 5 cm, peripheral enhancement, peri-ulcer edematous areas, and intratumoral cystic areas (hemorrhage or necrosis). If 2 to 4 criteria are observed, then there is high probability of malignancy (specificity 90%, sensitivity 61%). However, MPNST definitive diagnosis is confirmed through histology [7]. In our case, a biopsy was carried out along with histology which was sent in Europe, and confirmed the diagnosis 6 weeks later. This biopsy revealed a proliferation of monomorphic malignant spindle cell tumors with predominance of hemangiopericytoma structure. The tumor morphological and phenotypic profile suggested a Malignant Peripheral Nerve Sheath Tumor. Based on immunohistochemical investigation, there is no specific MPNST markers in the literature. Most commonly used markers are S-100 protein, positive in 50% of cases. Similarly, the dosage of leu-7 and myelin basic protein can be positive in 50% of cases. However HMB45 and cytokeratin are negative [20]. Our patient passed away a month after the tumor resection. Several other authors made the same observation about the prognosis of this medical condition [21] [22] [23] [24]. In 1993, Seppala *et al.* reported that five patients with primary intradural MPNST died between 2 months and 6 years after extended metastatic surgery [21]. They noted that local recurrence and metastases were typical, even after an apparently complete resection. In the narrow spinal canal, radical lumpectomy with a margin of normal tissue is almost never possible without causing neurological injury. Incomplete lumpectomy and the release of highly malignant cells could be the cause of recurrence and metastases [25]. The poor health facilities in sub-Saharan Africa give us no other option than sending our surgical specimen abroad to refine the diagnosis. However, the too long delay-time have adverse consequences on post-surgery care and support. Although all authors agree that the treatment of Malignant Peripheral Nerve Sheath Tumor is primarily surgical [26], post-surgery radiation therapy is indicated in high grade MPNST or when resection margins are invaded [13]. For Kar. M and al in 2006, large or deep tumors are also an indication to adjuvant radiotherapy [27]. We could probably overcome life-threatening condition if post survey radiation therapy was carried out. In all cases, MPNST prognosis is also poor [20]-[28]. The 5-year survival rate is 20% to 50% [29]. The overall development depends on the histological grade of the tumor, its size, location, whether or not it is associated with NF1, and finally the possibility and quality of primary surgery [30]. The risk of local recurrence is 40% to 65% [31]. Metastases are blood-borne or follow the pathway of nerve sheaths. Distant metastases are located in the lungs, liver and bones. They appear in an average period of two years. Such a period is shorter when there is NF1 [12]-[32].

4. Conclusion

MPNST is a rare and dreadful life-threatening disease. It presents a clinical polymorphism depending on its specific anatomic site, which can turn out to be slow spinal cord compression. But this is uncommon as MPNST has low osseous tropism. MRI remains the preferred examination for diagnosing spinal cord compression but not for MPNST. The definitive diagnosis is based on histology. In sub-Saharan Africa, the difficulties in diagnosing and the challenging post-surgery follow-up of this condition makes this tumor a life-threatening disease.

Conflict of Interest

The authors declare that there is no conflict of interest regarding the publication of this paper.

References

- [1] Bagan, J.V., Murillo, J., Jimenez, Y., Poveda, R., Milian, M.A., Sanchis, J.M., *et al.* (2005) Avascular Jaw Osteonecrosis in Association with Cancer Chemotherapy: Series of 10 Cases. *Journal of Oral Pathology & Medicine*, **34**, 120-123. <https://doi.org/10.1111/j.1600-0714.2004.00269.x>
- [2] Neville, B.W., Hann, J., Narang, R. and Garen, P. (1991) Oral Neurofibrosarcoma Associated with Neurofibromatosis Type I. *Oral Surgery, Oral Medicine, Oral Pathology, Oral Radiology*, **72**, 456-461. [https://doi.org/10.1016/0030-4220\(91\)90560-Y](https://doi.org/10.1016/0030-4220(91)90560-Y)
- [3] Lee, J.H., Lee, H.K., Choi, C.G., Suh, D.C., Lee, K.S. and Khang, S.K. (2001) Malignant Peripheral Nerve Sheath Tumor in the Parapharyngeal Space: Tumor Spread through the Eustachian Tube. *American Journal of Neuroradiology*, **22**, 748-750.
- [4] Asavamongkolkul, A., Jiranantakan, T., Waikakul, S., Phompitaksa, K. and Muangsomboon, S. (2001) Malignant Peripheral Nerve Sheath Tumor with Neurofibromatosis Type 1: A 2-Case Report and Review of the Literature. *Journal of the Medical Association of Thailand*, **84**, 285-293.
- [5] Bullock, M.J., Bedard, Y.C., Bell, R.S. and Kandel, R. (1995) Intraosseous Malignant Peripheral Nerve Sheath Tumor. Report of a Case and Review of the Literature. *Archives of Pathology & Laboratory Medicine*, **119**, 367-370.
- [6] Chick, G., Alnot, J.Y. and Silbermann-Hoffman, O. (2003) Multiple Peripheral Nerve Tumors: Update and Review of the Literature. *Chirurgie de la Main*, **22**, 131-137. [https://doi.org/10.1016/S1297-3203\(03\)00038-6](https://doi.org/10.1016/S1297-3203(03)00038-6)
- [7] Hajjad, T., El Mazouz, S., Gharib, N., El, A. and Une, A. (2015) Une tumeur maligne des gaines des nerfs périphériques compliquant la maladie de Von Recklinghausen. *Pan African Medical Journal*, **21**, 176-179. <https://doi.org/10.11604/pamj.2015.21.176.7035>
- [8] Charfeddine, I., Mnejja, M., Hammami, B., Hasnaoui, M., Hadj, K.A., Frikha, I., *et al.* (2009) Neurofibromatosis Type 1 Revealed by Malignant Peripheral Nerve Sheath Tumor. *Rev Laryngol Otol Rhinol*, **130**, 327-330.
- [9] Terry, D.G., Sauser, D.D. and Gordon, M.D. (1998) Intraosseous Malignant Peripheral Nerve Sheath Tumor in a Patient with Neurofibromatosis. *Skeletal Radiology*, **27**, 346-349. <https://doi.org/10.1007/s002560050395>

- [10] Dunnick, N.R. (2017) Image Interpretation Session: 1999. Intraosseous Malignant Peripheral Nerve Sheath Tumor (Malignant Schwannoma) in a Patient with Neurofibromatosis. *Radiographics*, **20**, 271-273.
- [11] Bilgic, B., Ates, L.E., Demiryont, M., Ozger, H. and Dizdar, Y. (2003) Malignant Peripheral Nerve Sheath Tumors Associated with Neurofibromatosis Type 1. *Pathology & Oncology Research*, **9**, 201-205. <https://doi.org/10.1007/BF03033740>
- [12] Soualhi, M., El Ouazani, H., Chaibainou, A., Bouchentouf, R., El Ftouh, M., Mouline, S., *et al.* (2004) Epithelioid Malignant Peripheral Nerve Sheath Tumor. A Case Report. *Revue De Pneumologie Clinique*, **60**, 50-54. [https://doi.org/10.1016/S0761-8417\(04\)72084-2](https://doi.org/10.1016/S0761-8417(04)72084-2)
- [13] Meis, J.M., Enzinger, F.M., Martz, K.L. and Neal, J.A. (1992) Malignant Peripheral Nerve Sheath Tumors (Malignant Schwannomas) in Children. *The American Journal of Surgical Pathology*, **16**, 694-707. <https://doi.org/10.1097/0000478-199207000-00008>
- [14] Raney, B., Schnauffer, L., Ziegler, M., Chatten, J., Littman, P. and Jarrett, P. (1987) Treatment of Children with Neurogenic Sarcoma. Experience at the Children's Hospital of Philadelphia, 1958-1984. *Cancer*, **59**, 1-5. [https://doi.org/10.1002/1097-0142\(19870101\)59:1<1::AID-CNCR2820590105>3.0.CO;2-A](https://doi.org/10.1002/1097-0142(19870101)59:1<1::AID-CNCR2820590105>3.0.CO;2-A)
- [15] Tekaya, R., Hamdi, W., Azzouz, D., Bouaziz, M., Jaafoura, M.H., Ladeb, M.F., *et al.* (2008) [Cervicobrachial Neuralgia Revealing Neurosarcoma]. *Revista De Neurologia*, **164**, 82-86. <https://doi.org/10.1016/j.neurol.2007.07.006>
- [16] De Bree, R., van der Valk, P., Kuik, D.J., van Diest, P.J., Doornaert, P., Buter, J., *et al.* (2006) Prognostic Factors in Adult Soft Tissue Sarcomas of the Head and Neck: A Single-Centre Experience. *Oral Oncology*, **42**, 703-709. <https://doi.org/10.1016/j.oraloncology.2005.11.009>
- [17] Hruban, R.H., Shiu, M.H., Senie, R.T. and Woodruff, J.M. (1990) Malignant Peripheral Nerve Sheath Tumors of the Buttock and Lower Extremity. A Study of 43 Cases. *Cancer*, **66**, 1253-1265. [https://doi.org/10.1002/1097-0142\(19900915\)66:6<1253::AID-CNCR2820660627>3.0.CO;2-R](https://doi.org/10.1002/1097-0142(19900915)66:6<1253::AID-CNCR2820660627>3.0.CO;2-R)
- [18] Henry, I. (1995) Neurofibromatose de Type 1 ou Maladie de Von Recklinghausen: De nombreuses questions restent posées. *Medicine Sciences*, **11**, 93-98. <https://doi.org/10.4267/10608/2164>
- [19] Ben Hamouda, M., Sghaier, S., Bergaoui, N., Baccari, S., Chaabene, M., Jaafoura, H., *et al.* (2002) Value of Imaging in the Diagnosis of Peripheral Neurofibrosarcomas: A Case Report. *La Tunisie Medicale*, **80**, 718-721.
- [20] Beegun, I., Bottrill, I.D. and Hollowood, K. (2009) Malignant Peripheral Nerve Sheath Tumours of the Infraorbital Nerve: Case Report and Literature Review. *The Journal of Laryngology & Otology*, **123**, 466-470. <https://doi.org/10.1017/S002221510800265X>
- [21] Seppälä, M.T. and Haltia, M.J. (1993) Spinal Malignant Nerve-Sheath Tumor or Cellular Schwannoma? A Striking Difference in Prognosis. *Journal of Neurosurgery*, **79**, 528-532. <https://doi.org/10.3171/jns.1993.79.4.0528>
- [22] Thomeer, R.T., Bots, G.T., van Dulken, H., Luyendijk, W. and Helle, P. (1981) Neurofibrosarcoma of the Cauda Equina. Case Report. *Journal of Neurosurgery*, **54**, 409-411. <https://doi.org/10.3171/jns.1981.54.3.0409>
- [23] Valdueza, J.M., Hagel, C., Westphal, M., Hänsel, M. and Herrmann, H.D. (1991) Primary Spinal Malignant Schwannoma: Clinical, Histological and Cytogenetic

- Findings. *Neurosurgical Review*, **14**, 283-291. <https://doi.org/10.1007/BF00383263>
- [24] Acharya, R., Bhalla, S. and Sehgal, A.D. (2001) Malignant Peripheral Nerve Sheath Tumor of the Cauda Equina. *Neurological Sciences*, **22**, 267-270. <https://doi.org/10.1007/s100720100009>
- [25] Yone, K., Ijiri, K., Hayashi, K., Yokouchi, M., Takenouchi, T., Manago, K., *et al.* (2004) Primary Malignant Peripheral Nerve Sheath Tumor of the Cauda Equina in a Child Case Report. *Spinal Cord*, **42**, 199-203. <https://doi.org/10.1038/sj.sc.3101567>
- [26] Minovi, A., Basten, O., Hunter, B., Draf, W. and Bockmühl, U. (2007) Malignant Peripheral Nerve Sheath Tumors of the Head and Neck: Management of 10 Cases and Literature Review. *Head Neck*, **29**, 439-445. <https://doi.org/10.1002/hed.20537>
- [27] Kar, M., Deo, S.V.S., Shukla, N.K., Malik, A., DattaGupta, S., Mohanti, B.K., *et al.* (2006) Malignant Peripheral Nerve Sheath Tumors (MPNST)—Clinicopathological Study and Treatment Outcome of Twenty-Four Cases. *World Journal of Surgical Oncology*, **4**, 55. <https://doi.org/10.1186/1477-7819-4-55>
- [28] Sabesan, T., Hussein, K. and Ilankovan, V. (2008) Malignant Peripheral Nerve Sheath Tumour of the Parapharyngeal Space in a Patient with Neurofibromatosis Type 1. *British Journal of Oral and Maxillofacial Surgery*, **46**, 585-587. <https://doi.org/10.1016/j.bjoms.2008.02.003>
- [29] Topal, O., Yilmaz, T. and Oğretmenoğlu, O. (2004) Giant Malignant Peripheral Nerve Sheath Tumor of the Neck in a Patient with Neurofibromatosis-1. *International Journal of Pediatric Otorhinolaryngology*, **68**, 1465-1467. <https://doi.org/10.1016/j.ijporl.2004.06.005>
- [30] Pfeiffer, J., Arapakis, I., Boedeker, C.C. and Ridder, G.J. (2008) Malignant Peripheral Nerve Sheath Tumour of the Paranasal Sinuses and the Anterior Skull Base. *Journal of Cranio-Maxillo-Facial Surgery*, **36**, 293-299. <https://doi.org/10.1016/j.jcms.2007.11.003>
- [31] Malone, J.P., Lee, W.-J. and Levin, R.J. (2017) Clinical Characteristics and Treatment Outcome for Nonvestibular Schwannomas of the Head and Neck. *American Journal of Otolaryngology*, **26**, 108-112. <https://doi.org/10.1016/j.amjoto.2004.08.011>
- [32] Yamaguchi, U., Hasegawa, T., Hirose, T., Chuman, H., Kawai, A., Ito, Y., *et al.* (2003) Low Grade Malignant Peripheral Nerve Sheath Tumour: Varied Cytological and Histological Patterns. *Journal of Clinical Pathology*, **56**, 826-830. <https://doi.org/10.1136/jcp.56.11.826>