



To Assess the Effectiveness of Planned Teaching on Knowledge Regarding Harlequin Ichthyosis among Post Basic B.Sc Nursing Students

Anushri Kale^{1*} and Bibin Kurian¹

¹Department of Child Health Nursing, Smt. Radhikabai Memorial College of Nursing, Datta Meghe Institute of Medical Sciences (DU), Sawangi (M), Wardha, India.

Authors' contributions

This work was carried out in collaboration between both authors. Both authors read and approved the final manuscript.

Article Information

DOI: 10.9734/JPRI/2021/v33i47A33053

Editor(s):

(1) Dr. Syed A. A. Rizvi, Nova Southeastern University, USA.

Reviewers:

(1) Maria Gicela Pérez Hernández, University of Colima, Mexico.

(2) Hasan Zafer Acar, Girne American University, Cyprus.

Complete Peer review History: <https://www.sdiarticle4.com/review-history/74731>

Study Protocol

Received 01 August 2021

Accepted 05 October 2021

Published 29 October 2021

ABSTRACT

Background: Harlequin ichthyosis is an uncommon, extreme type of skin issue related with gigantic thickening of skin over whole body. The primary case was accounted for in 1750 by Reverend Oliver Hart. The general occurrence is 1 out of 300,000 births. Around 200 cases have been accounted for all through the world. In 1984, a newborn child with this issue was brought into the world in Pakistan and the child lived till 2008. One more such birth was recorded in the USA in 1994. As of late, one case was accounted for in June 2016 at Nagpur, India. A Harlequin child was brought into the world to a youthful couple in Lata Mangeshkar Hospital.

Objectives: To assess the existing knowledge regarding Harlequin Ichthyosis among P.B.Bsc nursing students. To assess the effectiveness of planned teaching on knowledge regarding Harlequin Ichthyosis among P.B.Bsc nursing students. To associate the post-test knowledge regarding Harlequin Ichthyosis among P.B.Bsc nursing students with selected demographic variables.

Materials and Methods: A one group pre-test and post-test research design study will undertaken to assess the effectiveness of planned teaching on knowledge regarding harlequin ichthyosis among P.B.B.Sc nursing students of selected colleges.

Expected Results: There will be significant association between pre-test and post-test knowledge regarding Harlequin ichthyosis among P.B.Bsc nursing students.

Keywords: Knowledge; planned teaching; and harlequin ichthyosis.

1. INTRODUCTION

The other names of this condition are Harlequin baby syndrome, HI, Ichthyosis Congenita and Harlequin Fetus Type. This is an extremely rare and severe inherited (genetic) ichthyosis. There are approximately five such children born in the UK each year and some may be stillborn. The name comes from the appearance of the skin at birth[1].

Harlequin ichthyosis is the most extreme type of autosomal latent intrinsic ichthyosis[2]. Harlequin ichthyosis is portrayed by a significant thickening of the keratin layer in fetal skin[3]. The influenced youngster is brought into the world with a gigantic, horny shell of thick, plate like scale and constriction irregularities of the eyes, ears, mouth, and appendages[4]. The term harlequin gets from the facial appearance and the three-sided and precious stone formed example of hyperkeratosis. The infant's mouth is pulled totally open, emulating a comedian's smile[5].

Checked eclabium and ectropion are available auxiliary to the tight, immovable skin. The ears might be missing or ineffectively developed[6]. The arms, feet, and digits have flexion contractures and might be hypoplastic. The skin boundary is seriously compromised, prompting unreasonable water misfortune, electrolyte irregularities, temperature dysregulation, and an expanded danger of hazardous infection[7]. The tight, armorlike scale can confine breath. Helpless taking care of and disabled gastrointestinal assimilation are common[8].

This illness essentially influences the skin. Different frameworks might be altogether undermined by the hyperkeratosis and corresponding distortions. Youngsters are regularly conceived rashly. The underlying hereditary anomaly in harlequin ichthyosis is a transformation in the lipid-carrier quality ABCA12 on chromosome 2[9].

Immunohistochemical assessment of the skin uncovers trademark anomalies in the design of lamellar granules and in the outflow of epidermal keratin. Before, harlequin ichthyosis was consistently deadly[10]. Further developed endurance has been accomplished with extreme steady consideration and fundamental retinoid treatment in the neonatal period. Patients who endure show a crippling, diligent ichthyosis like serious inherent ichthyosiform erythroderma[11].

Medical management-Ensure that the patient's airway, breathing, and circulation are stable after delivery. Early intubation may be required. Babies require intravenous access. Peripheral access may be difficult and umbilical cannulation may be necessary. Place infants in a humidified incubator. Monitor temperature, respiratory rate, heart rate, and oxygen saturation. Once stabilized, transfer newborn with harlequin ichthyosis to a NICU.

- Exposure keratitis results from ectropion of the eyelids. Apply ophthalmic lubricants frequently to protect the conjunctivae
- Bathe infants twice daily and use frequent wet sodium chloride compresses followed by application of bland lubricants to soften hard skin. Dilute bleach baths may reduce the risk of skin infection.
- Topical keratolytics (eg, salicylic acid) are not recommended in newborns because of potential systemic toxicity. Early retinoid treatment (by day 7) may require prompt consideration, as these medications can take some days to obtain.
- Tazarotene, a topical retinoid, has been reported to be beneficial.
- Intravenous fluids are almost always required. Consider excess cutaneous water losses in daily fluid requirement calculations. Monitor serum electrolyte levels. A risk of hypernatremic dehydration exists.
- Neonates with harlequin ichthyosis initially do not feed well and may require tube feeding.
- Maintain a sterile environment to avoid infection. Take frequent cultures of the skin. Growth of pathogenic organisms (eg, *Staphylococcus aureus*, *Pseudomonas aeruginosa*, *Klebsiella*) indicates risk of sepsis. Draw blood cultures because sepsis can occur quickly in affected infants.

1.1 Background of the Study

Inherited ichthyosis vulgaris and obtained ichthyosis vulgaris, individuals from a gathering of cutaneous problems of keratinization, seem comparable both clinically and histologically. The term ichthyosis is gotten from the old Greek root *ichthys*, which means fish. Albeit the similarity is fairly whimsical, it all things considered passes on the trademark elements of these illnesses.

References to ichthyosis have been found in antiquated clinical texts matured over 2000 years. Inherited ichthyosis vulgaris is an autosomal prevailing hereditary problem first apparent in youth. It is the most well-known type of ichthyosis, representing over 95% of ichthyosis cases. Transformations in qualities identifying with skin obstruction development produce it[12].

Harlequin ichthyosis is an uncommon, extreme type of skin problem related with huge thickening of skin over whole body. The primary case was accounted for in 1750 by Reverend Oliver Hart. The general occurrence is 1 out of 300,000 births[13]. Roughly 200 cases have been accounted for all through the world. In 1984, a newborn child with this problem was brought into the world in Pakistan and the child lived till 2008. One more such birth was recorded in the USA in 1994. As of late, one case was accounted for in June 2016 at Nagpur, India. A Harlequin child was brought into the world to a youthful couple in Lata Mangeshkar Hospital[14].

1.2 Need for the Study

Harlequin ichthyosis is an uncommon type of inborn ichthyosis with a general rate of 1 of every 300,000 births. Inside nursing care measure comprising of palliative and preventive consideration given to patient. Patients by and large pass on in the primary long stretches of life because of sepsis, drying out and disabled thermoregulation. Observing of day by day body weight and liquid status; every day checking of electrolytes to forestall hypernatremic parchedness during the primary week and from there on dependent on quiet's condition. Healthy skin with day by day washing[15].

Indeed, even with escalated care (counting treatment with Acretin), guess is poor and most children bite the dust soon after conveyance because of contamination, heat misfortune, parchedness, electrolytic unsettling influences (eg, hypernatremia), or respiratory trouble. There are not many reports of pre-birth determination of Harlequin ichthyosis. Its doubt dependent on ultrasound (US) assessment is very troublesome. As the disclosure of the ABCA 12 change, the determination might be affirmed by chorionic villus or amniotic liquid example. We report an instance of an effective pre-birth conclusion of Harlequin ichthyosis during the third-trimester US assessment in a connected couple with no set of experiences of the illness[16].

Skin hindrance work is uniquely hindered, which can prompt hypernatremic parchedness, disabled thermoregulation, expanded metabolic requests, and expanded danger of respiratory brokenness and disease. By and large, babies with HI didn't get by past the neonatal period; notwithstanding, late advances in neonatal concentrated consideration and composed multidisciplinary the board have incredibly further developed endurance. In this audit, the creators consolidate the developing HI writing with their aggregate encounters to give a far reaching survey of the administration of youngsters with HI[17].

2. METHODOLOGY

The study will based on evaluatory research approach with One group, pre-test post-test research design. The study will be carried out Smt. Radhikabai Meghe Memorial College of Nursing Sawangi, Wardha. A Convenient sampling technique will be used. Data will be collected from P.B.B.Sc nursing students by self-structured questionnaire will be assess the effectiveness of planned teaching on knowledge regarding harlequin ichthyosis. After planned teaching the self-structured questionnaire will be filled up simultaneously by nursing students.

2.1 Tools Description

The intervention will be plan on giving lesson plan on Harlequin Ichthyosis for 45 minutes. Before that I will take pre-test on Harlequin Ichthyosis on Post Basic B.Sc Nursing students for 30 mintues. I will plan self-structured questionnaire regarding Harlequin Ichthyosis which will help me to know the knowledge they have regarding Harlequin Ichthyosis. After that planned teaching will be delivered to Post Basic B.Sc nursing students. After 7 days again I will take post-test on same self-structured questionnaire which I had given in a pre-test for 30 minutes then I will analysis the data and make the result.

2.1.1 Inclusion criteria

- Students who will willing to participate in this study.
- The students who are available during data collection.

2.1.2 Exclusion criteria

- Students who are sick.

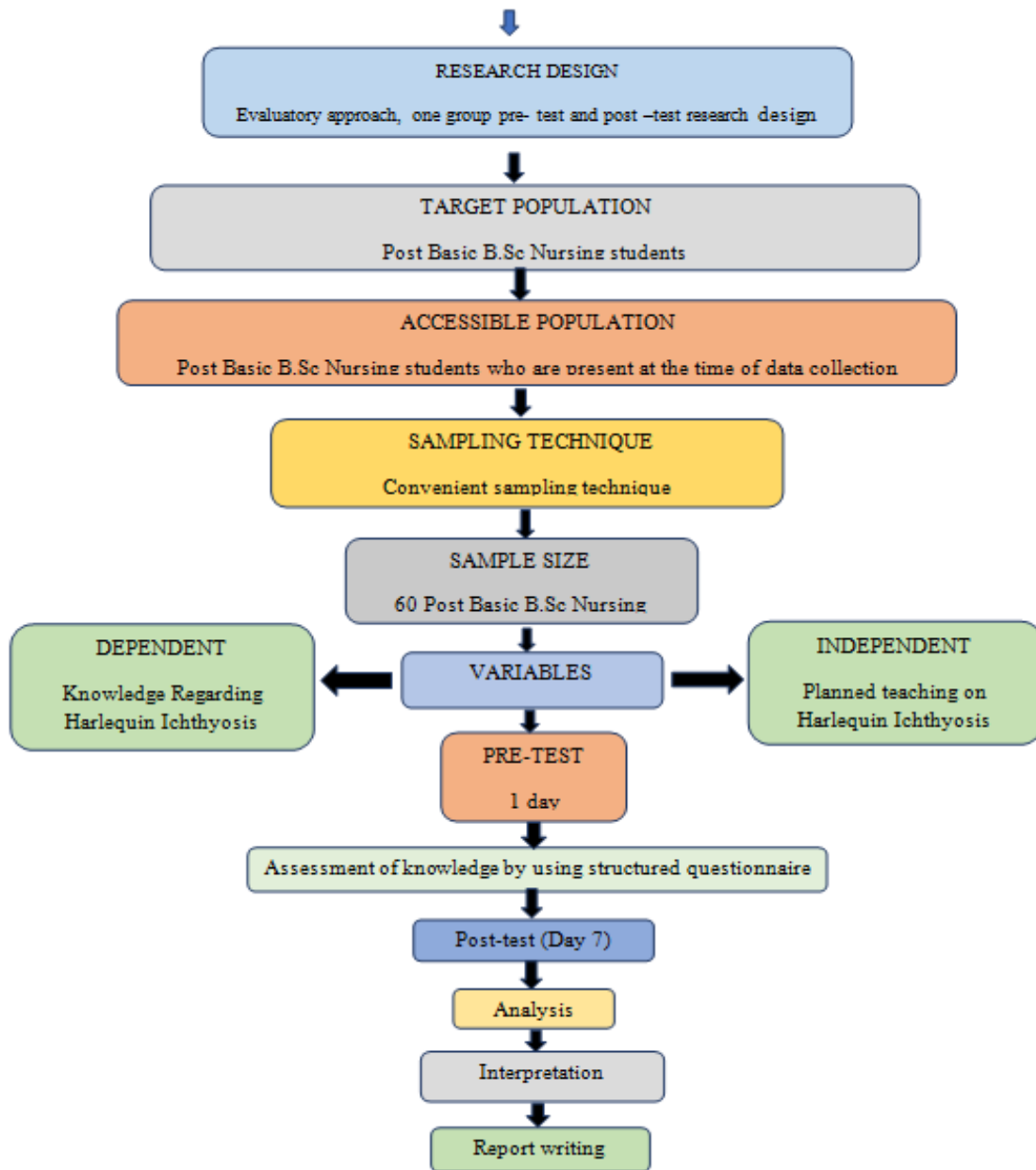


Fig. 1. Sample analysis

2.2 Sample Size

In this study sample size will be 60.

2.3 Limitation

This is limited to Post Basic B.Sc nursing students.

2.4 Data Management and Monitoring

The demographic variable are age, gender, source of knowledge. Assess the effectiveness of

planned teaching on knowledge regarding Harlequin Ichthyosis. One group pre-test and post-test will be taken for study.

2.5 Statistical Analysis

Statistical analysis will be done by descriptive and inferential statistics.

3. EXPECTED OUTCOMES/RESULTS

The study is planned to assess the effectiveness of planned teaching on knowledge regarding

harlequin ichthyosis among P.B.B.Sc students. There will be significant association between pre-test and post-test knowledge regarding harlequin ichthyosis.

4. DISCUSSION

Harlequin ichthyosis is an uncommon type of intrinsic ichthyosis that can introduce many difficulties all through a lifetime, yet particularly during the neonatal period. A comprehension of the ABCA12 transformation and skin boundary disturbance gives a premise to treatment. Forceful and steady consideration from an interdisciplinary group is needed for powerful administration; furthermore, without information despite what is generally expected, the creators trust it is prudent to found early retinoid treatment [18].

Harlequin ichthyosis is an incredibly uncommon and genuine condition with high death rates that can be exceptionally trying for a neonatal group. Maybe the new planning of the human genome will clarify the reason and result in a more powerful strategy for diagnosing and treating this deforming sickness. Until such a period, support guardians and give them admittance to however much data and however many assets as could reasonably be expected.

Pre-birth analysis of Harlequin ichthyosis is very troublesome in lowrisk patients (ie, patients with no family ancestry). A large portion of the trademark provisions will possibly become clear later in pregnancy when confined skin advancement turns into an impediment to fetal development and developments. Indeed, even at third-trimester US assessment, in case there is no doubt, it is very difficult to analyze this element. A large portion of the distributed reports were either cases in which the finding was made after conveyance or in patients with recently influenced kids. Up until now, just 13 instances of pre-birth doubt of Harlequin ichthyosis dependent on US assessment in generally safe patients have been distributed, and just in nine of them was the conclusion affirmed by amniotic liquid or chorionic villus examining. As the skin is too dry, the hatchling can't develop or move true to form. This clarifies the development limitation, microcephaly, and the level nose and hypoplastic ears[19]. There is extending of the periorbital and perioral regions causing tenacious opening of the eyes and mouth, ectropion, and eclabium. The furthest points become hardened and fixed in flexed position, with held hands, clubfeet (distal

arthrogryposis), and restriction of fetal developments. The restricted body development may likewise weaken lung improvement. Other US discoveries are polyhydramnios, echogenic amniotic liquid (the snow-drop sign) brought about by drifting stripped skin, subcutaneous edema (especially at the distal piece of the appendages), and short umbilical rope. 3D or 4D US assessment might be very helpful to more readily picture these elements. The thick and dark amniotic liquid found at amniocentesis for this situation might be clarified by the stripping of the skin. During work, the amniotic liquid was loaded up with scale-like pieces of skin and the fetal skin contact was cowhide like due to the hypertrophic plaques of dry skin. The danger of an influenced ensuing pregnancy is 25 and in this way couples ought to be offered preimplantation hereditary conclusion[20].

5. CONCLUSION

Conclusion will be drawn from the statistical analysis.

CONSENT

As per international standard or university standard, respondents' written consent will be collected and preserved by the author(s).

ETHICAL APPROVAL

Study was approved by the institutional Ethics Committee (letter no- DMIMS (DU)/IEC/2021/254) and the study will be conducted with the ethical guidelines by institutional Ethics Committee on Human research.

COMPETING INTERESTS

Authors have declared that no competing interests exist.

REFERENCES

1. Kurian B. Harlequin Ichthyosis Disorder. *Inter Jour of Adva in Nur Manag.* 2016;4(3):301.
2. Harlequin-type ichthyosis. In: Wikipedia [Internet]. 2021 [cited 2021 Jul 23]. Available from: https://en.wikipedia.org/w/index.php?title=Harlequin_type_ichthyosis&oldid=1030129723
3. Hovnanian A. Harlequin ichthyosis unmasked: a defect of lipid transport. *J Clin Invest.* 2005;115(7):1708–10.

4. Harlequin Ichthyosis: Background, Etiology, Epidemiology [Internet]. [cited 2021 Jul 23]. Available: <https://emedicine.medscape.com/article/1111503-overview>
5. Patil P, Patil A, Verma J, Ghosh G. Recurrent Congenital Ichthyosis in Newborn: A Case Report. *International Journal of Medical Research and Review*. 2013;1(2):71–3.
6. Lawlor F. Progress of a harlequin fetus to nonbullous ichthyosiform erythroderma. *Pediatrics*. 1988;82(6):870-3. [Medline].
7. Lefevre C, Audebert S, Jobard F, et al. Mutations in the transporter ABCA12 are associated with lamellar ichthyosis type 2. *Hum Mol Genet*. 2003;12(18):2369-78. [Medline].
8. Ahmed H, O'Toole EA. Recent advances in the genetics and management of harlequin ichthyosis. *Pediatr Dermatol*. 2014;31(5):539-46. [Medline].
9. Kelsell DP, Norgett EE, Unsworth H, Teh M-T, Cullup T, Mein CA, et al. Mutations in ABCA12 Underlie the Severe Congenital Skin Disease Harlequin Ichthyosis. *Am J Hum Genet*. 2005;76(5):794–803.
10. Akiyama M, Yoneda K, Kim SY, Koyama H, Shimizu H. Cornified cell envelope proteins and keratins are normally distributed in harlequin ichthyosis. *J Cutan Pathol*. 1996;23:571–575 [PubMed] [Google Scholar]
11. Brooks-Wilson A, Marcil M, Clee SM, Zhang LH, Roomp K, van Dam M, Yu L, et al. Mutations in ABC1 in Tangier disease and familial high-density lipoprotein deficiency. *Nat Genet*. 1999;22:336–345 [PubMed] [Google Scholar]
12. Hereditary and Acquired Ichthyosis Vulgaris: Background, Pathophysiology, Etiology. 2021 [cited 2021 Aug 29]; Available: <https://emedicine.medscape.com/article/1112753-overview>
13. Akiyama M, Sakai K, Sugiyama-Nakagiri Y, Yamanaka Y, McMillian JR, Sawamura D, Niizeki H, Miyagawa S, Shimizu H. Compound heterozygous mutations including a de novo missense mutation in ABCA12 led to a case of harlequin ichthyosis with moderate clinical severity. *J Invest Dermatol*. 2006;126(7):1518-23Epub.
14. India's first case of Harlequin Ichthyosis reported in Nagpur | India News – India TV [Internet]. [cited 2021 Jul 23]. Available: <https://www.indiatvnews.com/news/india-baby-born-with-no-external-skin-india-s-first-case-of-harlequin-ichthyosis-reported-in-nagpur-333994>
15. Shruthi B, Nilgar BR, Dalal A, Limbani N. Harlequin ichthyosis: A rare case. *Turk J Obstet Gynecol*. 2017;14(2):138–40.
16. Kale KA, Ghonge NP, Kaul A. Prenatal diagnosis of congenital harlequin ichthyosis with fetal MRI. *Indian J Radiol Imaging*. 2019;29(4):448–51.
17. Glick JB, Craiglow BG, Choate KA, Kato H, Fleming RE, Siegfried E, et al. Improved Management of Harlequin Ichthyosis With Advances in Neonatal Intensive Care. *Pediatrics*. 2017;139(1):e20161003.
18. Brooks-Wilson A, Marcil M, Clee SM, Zhang LH, Roomp K, van Dam M, Yu L, et al. Mutations in ABC1 in Tangier disease and familial high-density lipoprotein deficiency. *Nat Genet*. 1999;22:336–345 [PubMed] [Google Scholar]
19. Buxman MM, Goodkin PE, Fahrenback WH. Harlequin ichthyosis with epidermal lipid abnormality. *Arch Dermatol*. 1979;115:189–193 [PubMed] [Google Scholar]
20. Choate KA, Williams ML, Elias PM, Khavari PA. Transglutaminase 1 expression in a patient with features of harlequin ichthyosis: case report. *J Am Acad Dermatol*. 1998;38:325–329 [PubMed] [Google Scholar]

© 2021 Kale and Kurian; This is an Open Access article distributed under the terms of the Creative Commons Attribution License (<http://creativecommons.org/licenses/by/4.0>), which permits unrestricted use, distribution, and reproduction in any medium, provided the original work is properly cited.

Peer-review history:
The peer review history for this paper can be accessed here:
<https://www.sdiarticle4.com/review-history/74731>