

Surge and Scare of Mucormycosis in the Backdrop of COVID-19 Pandemic

OOHA ANYAPU¹, SREEDEVI PARVATINI², PAPANATNAM KALIVARAPU³, RAJANI KUNA⁴, JAGADEESWARI SUVVARI⁵

ABSTRACT

Introduction: Mucormycosis is a rare opportunistic fungal infection. During the second wave of Coronavirus Disease-2019 (COVID-19), a remarkable increase in mucormycosis cases was observed. Diabetes mellitus is an independent risk factor for both mucormycosis and COVID-19.

Aim: To assess the incidence of mucormycosis cases in COVID-19 infected and non COVID-19 infected patients and also to assess the related co-morbid conditions during the second wave of COVID-19 pandemic.

Materials and Methods: This cross-sectional study was conducted from 15th May 2021 to 15th July 2021 in the Department of Pathology, GGH/Government Medical College, Srikakulam, Andhra Pradesh, India. The study included 63 cases of mucor suspects. The parameters analysed in this study were age, sex, COVID-19 status, co-morbidities, steroid status and radiological findings. A descriptive analysis was made from the data obtained. The information was analysed in data spreadsheets using Microsoft office excel 2010.

Results: Out of total 63 mucor suspects, 60 (95.2%) cases tested positive for COVID-19 and 44 (73.3%) cases of them received corticosteroid treatment. Mean age group of 41-50 years with 27 (42.8%) cases with a male preponderance of 49 (77.7%) cases was noted. The most common identified risk factor was diabetes mellitus seen in 22 (34.9%) cases and diabetes associated with hypertension in 14 (22.2%) of the cases. Mucormycosis fungal hyphae were noted in 49 (77.7%) of cases on routine histopathological examination stain and 47 (74.6%) of the cases by special stains for confirmation.

Conclusion: In the present study, it was observed that mucormycosis infection was most commonly seen in COVID-19 infected patients in post COVID-19 phase and also in minority of non COVID-19 infected cases with prior debilitating conditions. Therefore, it was concluded that, mucormycosis was positively associated with COVID-19 infected patients who have co-morbidities like diabetes mellitus and history of steroid usage.

Keywords: Angioinvasion, Coronavirus disease-2019, Cytokine storm, Diabetes mellitus, Fruiting bodies, Grocott-gomori's methenamine silver stain, Periodic acid-schiff stain

INTRODUCTION

Mucormycosis is a very rare opportunistic fungal infection [1]. This angioinvasive infection is caused by fungi of the order Mucorales which includes *Rhizopus*, *Mucor*, *Rhizomucor*, *Cunninghamella* and *Absidia* [2]. Its incidence differs worldwide from 0.005 to 1.7 per million population. In India, its prevalence is assessed to be 140 per million population which is approximately 80 times greater than in developed countries [3]. It is characterised by rapid progression, high morbidity and high mortality in the absence of early diagnosis and treatment [4].

The COVID-19 is caused by Severe Acute Respiratory Syndrome Coronavirus-2 (SARS-CoV-2). It is associated with a wide array of opportunistic fungal pathogens. Main causative organisms for co-infection in people with COVID-19 have been reported as mucormycosis and *aspergillus* [5]. The second wave of COVID-19 has affected India substantially, with the highest number of cases being more than 0.4 million as per May 7, 2021, and has declined since. As our country continues to achieve consistency over the present condition, another impending hazard has emerged in the form of COVID-19 associated mucormycosis [6]. The rise has been perceived globally, but is exceptionally high in Asian continent. During the second wave of COVID-19, a remarkable increase in mucormycosis cases was observed, which is probably contributed to the immune dysregulation caused by the virus itself and usage corticosteroids, especially in patients with uncontrolled diabetes mellitus [7].

India has a very high prevalence rate of type 2 diabetes mellitus. Diabetes mellitus is an independent risk factor for both mucormycosis and COVID-19 infection. Following the rise of COVID-19 associated mucormycosis, Government of India directive, has named

mucormycosis as a notifiable disease in many states of India on May 10th 2021 [3].

Other risk factors for mucormycosis are organ transplantation, chemotherapy, neutropenia, Human Immunodeficiency Virus/Acquired Immune Deficiency Syndrome (HIV/AIDS), long-term high dose corticosteroid use, immunosuppressive therapy, iron overload or haemochromatosis, protein-calorie malnutrition, skin injury due to surgery, burns or wounds. It has emerged as a major life-threatening complication in patients undergoing haemodialysis. Intravenous drug abusers may inject spores and may present with space occupying lesions of Central Nervous System (CNS) [8]. In diabetic ketoacidosis, it is demonstrated that the ketone bodies present in these patients are metabolised by a ketone reductase enzyme, which allows them to survive in acidic conditions; therefore, the rhino-cerebral form of mucormycosis mainly occurs in patients with diabetes, particularly diabetic ketoacidosis where the acid base balance is altered [9].

Aim of the study was to assess the various factors that are associated with substantial increase of mucormycosis cases during the second wave of COVID-19 and also to assess the incidence of mucormycosis cases in COVID-19 infected (active infection/post COVID-19 infection) and non infected patients and other co-morbid conditions during the second wave of COVID-19 pandemic.

MATERIALS AND METHODS

This cross-sectional study conducted in the Department of Pathology at Government Medical College, Srikakulam, Andhra Pradesh, India, between 15th May 2021 to 15th July 2021. This study was approved by Institutional Ethics Committee (EC Registration No: ECR/492/Inst/AP/2013/RR-16). A total of 63 specimens of mucor suspects

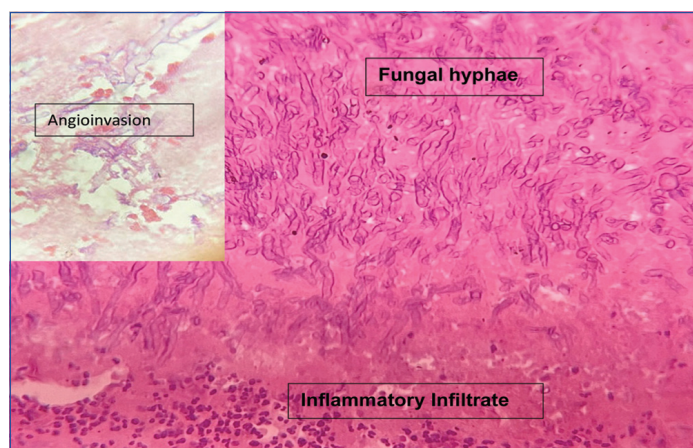
were received from Government general hospital within the study period, Srikakulam in 10% formalin. Various parameters like age and sex, duration of symptoms, COVID-19 status, co-morbidities, steroid status and radiological findings were recorded and analysed in the study.

Inclusion criteria: All cases of mucor suspects which were received from Government General Hospital, Srikakulam to the Department of Pathology during the study period irrespective of age, gender, ethnicity, COVID-19 status, drug usage and associations were included in the study.

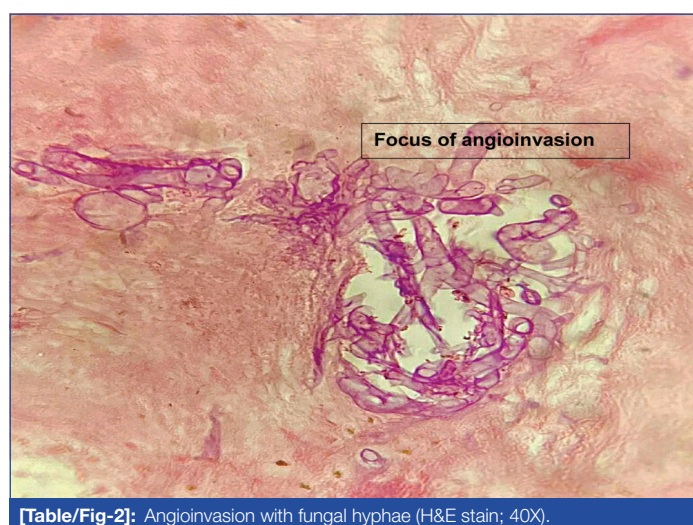
Exclusion criteria: Patients currently under treatment for mucormycosis, patients diagnosed elsewhere and referred here for treatment purposes, active bleeding at the site of the biopsy, non co-operative and non consent patient were excluded from the study.

Study Procedure

The specimens received in 10% formalin were adequately fixed and the sections were given from representative areas and some specimens were subjected entirely to embedding. The tissues were properly processed and paraffin embedded. Sections of 4-5 μ thickness were cut using a microtome, stained with Haematoxylin and Eosin (H&E), subjected to histopathological examination and further confirmed by using special stains for fungal elements with Periodic Acid-Schiff Stain (PAS) and Grocott-Gomori's Methenamine Silver Stain (GMS). Histological sections were reviewed for the presence and type of inflammation, fungal morphology, angioinvasion and presence of thrombosis and necrosis [Table/Fig-1,2].



[Table/Fig-1]: Broad, aseptate, right angled branching fungal hyphae of mucormycosis (H&E, 40X); Insert image- Fungal hyphae in blood vessel (H&E, 10X).



[Table/Fig-2]: Angioinvasion with fungal hyphae (H&E stain; 40X).

STATISTICAL ANALYSIS

A descriptive analysis was made from the data obtained. The information was analysed in data spreadsheets using Microsoft office excel 2010.

RESULTS

A total of 63 cases of mucor suspects were studied. In the present study, majority of the cases were seen in the age group of 41-50 years contributing to 27 (42.9%) of the cases. The youngest patient was 29-year-old and oldest was 70-year-old [Table/Fig-3].

Age (years)	Number of cases (%)	Female n (%)	Males n (%)
21-30 years	1 (1.6%)	0	1 (100%)
31-40 years	12 (19%)	2 (16.7%)	10 (83.3%)
41-50 years	27 (42.9%)	5 (18.5%)	22 (81.4%)
51-60 years	17 (27%)	5 (29.4%)	12 (70.6%)
61-70 years	6 (9.5%)	2 (33.3%)	4 (66.7%)
Total	63 (100%)	14 (22.2%)	49 (77.8%)

[Table/Fig-3]: Age-wise distribution and sex wise distribution of mucormycosis in the present study.

There was a predominance of male population with 49 (77.8%) of the cases compared to female population which attributed to 14 (22.2%) of the cases.

Out of 63 mucor suspects, 60 (95.2%) tested positive for COVID-19 infection and 3 (4.7%) tested negative for COVID-19. Out of 60 members tested positive for COVID-19 only 11 (17.4%) were in active phase of infection and 49 (81.6%) were in post COVID-19 infection phase.

Out of 60 members who tested positive for COVID-19, 44 (73.3%) members received steroids as part of treatment and 16 (25.3%) members did not receive steroids during hospitalisation owing to less severity of viral infection or due to home isolation. Of the 44 members who received corticosteroid treatment 24 (55.4%) were pre-diagnosed with diabetes mellitus.

Onset of symptoms were most commonly observed within seven days before hospital admission in 34 (54%) of the cases, followed by >28 days in 12 (19%) of the cases [Table/Fig-4].

Duration of onset of symptoms	Number of cases (%)
1-7 days	34 (54%)
8-14 days	6 (9.52%)
15-21 days	8 (12.7%)
22-28 days	3 (4.8%)
>28 days	12 (19%)

[Table/Fig-4]: Duration of onset of symptoms of mucormycosis in the present study.

Diabetes Mellitus seen in 22 (35%) of the cases was the most common identified risk factor, either independently or in association with other co-morbidities like hypertension 14 (23%) [Table/Fig-5].

Co-morbidities	Number of cases (%)
Diabetes mellitus	22 (35%)
Hypertension	9 (14.3%)
Diabetes mellitus and hypertension	14 (22.2%)
Hepatitis B surface antigen-positive	2 (3.2%)
Hypothyroidism	1 (1.6%)
Chemotherapy (breast carcinoma)	1 (1.6%)
No known co-morbidities	14 (22.2%)


[Table/Fig-5]: Co-morbidities associated with mucormycosis in the present study.

Most commonly affected sinus in mucormycosis according to CT/Computed Tomography/Magnetic Resonance Imaging (CT/MRI) findings was maxillary sinus, seen either in isolation in 5 (7.9%) of the cases or in varying combinations with other paranasal sinuses in 52 (82.5%) of the cases [Table/Fig-6].

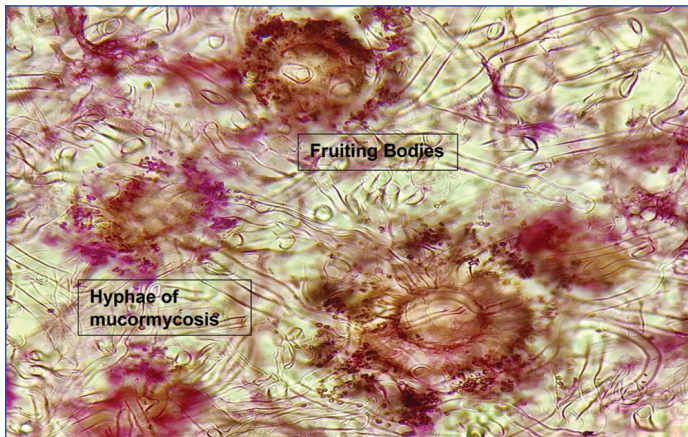
Maxilla was the most common affected part in 33 (67.3%) of the cases. Each case of mixed infection with both mucormycosis and aspergillus species and isolated infection of aspergillus were also seen [Table/Fig-7].

Computed tomography/Magnetic resonance imaging	Number of cases (%)
Pansinusitis	19 (30.2%)
Maxillary sinus	5 (7.9%)
Maxillary sinus and ethmoid sinus	13 (20.6%)
Maxillary sinus, ethmoid sinus and sphenoid sinus	20 (31.7%)
Extension into orbit and optic nerve	2 (3.2%)
Inferior and medial rectus muscle involvement	2 (3.2%)
Cavernous sinus involvement	1 (1.6%)
Temporal lobe extension	1 (1.6%)

[Table/Fig-6]: Radiological findings of mucormycosis patients in the present study.



[Table/Fig-10]: Black colour taken up by fungal hyphae due to reduction of silver nitrate to metallic silver ions (Grocott-gomori's methenamine silver stain, 10X).

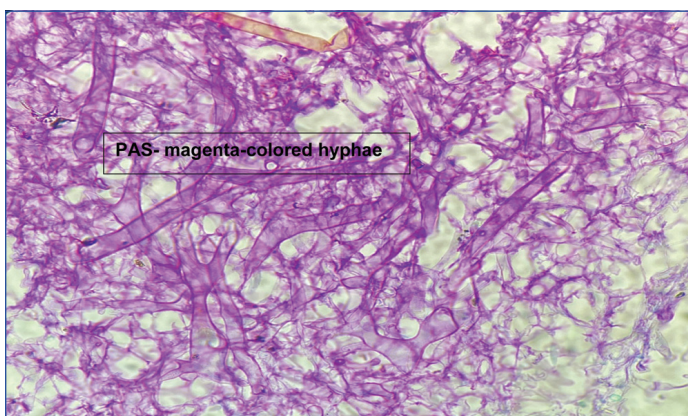


[Table/Fig-7]: Mixed fungal infection- Fruiting bodies of Aspergillus and fungal hyphae of mucormycosis (Periodic acid-schiff stain; 40X)

The [Table/Fig-8] showing mucormycosis fungal hyphae were noted in 49 (77.7%) of the cases on routine histopathological examination by H&E staining and in 47 (74.6%) of the cases by special stains for fungal morphology [Table/Fig-9,10].

Involved part	HPE-positive		PAS/GMS-positive	
	Number	%	Number	%
Maxilla	33	67.3%	32	68.1 %
Orbital	12	24.5%	12	25.5 %
Maxilla and orbital	3	6.1%	2	4.3%
Nasal	1	2.04%	1	2.12 %
Total	49	78%	47	74 %

[Table/Fig-8]: Histology and special stains positivity of mucormycosis in the present study.
HPE: Histopathological examination; PAS: Periodic acid-schiff stain; GMS: Grocott-gomori's methenamine silver stain



[Table/Fig-9]: Magenta coloured fungal hyphae (Periodic acid-schiff stain, 40X).

DISCUSSION

Mucormycosis is a rare opportunistic fungal infection, and its incidence is difficult to calculate precisely [3]. In study conducted by Singh AK et al., overall, 101 cases of mucormycosis in people with COVID-19 have been reported, of which 82 cases were from

India and 19 from the rest of the world [5]. Mucormycosis was predominantly seen in males (78.9%), both in people who were active (59.4%) or recovered (40.6%) from COVID-19. Pre-existing diabetes mellitus was present in 14.9%. Corticosteroid intake for treatment of COVID-19 was recorded in 76.3% of cases. The present study correlated with all the above-mentioned parameters except, a greater number of cases was observed in the people who have already recovered from COVID-19.

In the present study, maximum cases were between 41-50 years with male preponderance and diabetes mellitus identified as major comorbidity. In a similar study, conducted by Camara-Lemarray CR et al., the mean age was 39.9. Out of a total 14 cases, nine patients were male ten patients had diabetes mellitus as the underlying disease [10].

In study conducted by Bala K et al., the order of organ involvement is rhino-orbital (61.5%), cutaneous mucormycosis (31%) and mean age of the patients was 40.43 years, with a male predominance of 72% [11]. The present study correlated with the above study but we observed the association of COVID-19 exclusively with rhino-mucormycosis.

In the study conducted by Elzein F et al., a total of 18 patients with a median age of 43.5 years (range 13-72 years, 72% males) were identified [12]. The present study showed similar results.

A study conducted by Prakash H et al., found that 18% of the cases had diabetic ketoacidosis and 57% of patients had uncontrolled diabetes mellitus [13]. Similarly, study conducted by Patel A et al., has shown that, the predisposing factors associated with mucormycosis in Indians include DM (73.5%) [14]. These results correlate with the present study.

Mucormycosis comprises a group of infections caused by the fungi belonging to the order Mucorales and family Mucoraceae. *Rhizopus oryzae* is the most common cause of infection. They are seen in soil and decaying matter and are transmitted by airborne asexual spores. Most common route of entry is through inhalation of spores [15]. They are non pathogenic in immunocompetent individuals. In immunosuppressed patients, however, these otherwise non pathogenic organisms can cause a devastating infection with high mortality and morbidity [16].

There are specific pathophysiological features of COVID-19 that may permit secondary opportunistic fungal infections like mucormycosis. The immune dysregulation associated with COVID-19 leads to decrease of T lymphocytes, CD4+T, and CD8+T cells, which may alter innate immunity [17]. CD4+ and CD8+ cells produce cytokines such as Interleukin (IL) 4, IL-10, IL-17 and Interferon-gamma (IFN- γ) against the fungal hyphae. The delay in IFN- γ response, prolonged hyperinflammatory state and lower CD4 and CD8 cell numbers may exacerbate the 'cytokine storm' and therefore, increase severity of COVID-19 infection [2]. Steroid treatment given for COVID-19

patients affects the ability of bronchoalveolar macrophages to prevent germination of the spores [18].

Macrophages provide the first line of defence by phagocytosis and non oxidative killing of germinating sporangiospores. The polymorphonuclear leukocytes play a vital role in killing hyphae after germination by directly damaging walls of hyphae. If macrophages and neutrophils are compromised, the probability of a severe infection is greatly increased [15]. Pathogenic mechanisms involved in aggressiveness of the infection include reduction in phagocytic activity, fungal heme oxygenase enzyme, which promotes iron absorption needed for metabolism of the fungus and attainable amounts of iron as a result of displacement of protons by transferrin in patients with uncontrolled diabetes mellitus or diabetic ketoacidosis [2].

Rhinocerebral mucormycosis is the most common clinical form. It originates in paranasal sinuses and then extends orbit, face, nose, or brain. It most commonly presents with purulent or serosanguinous nasal discharge. Black necrotic eschar on the nasal turbinates or palate is very characteristic of this clinical form. Therefore, the name black fungus was given. Spread of infection to eye causes orbital pain, followed by ophthalmoplegia, proptosis, and finally loss of vision. Extension superiorly into the frontal lobe of brain causes lethargy, seizures [19].

On H&E-stained slides, hyphae are seen as broad (6-25 μ in width), aseptate/pauciseptate, thin walled, pleomorphic with irregular, non parallel contours. Branches arise haphazardous, often at right angles to the parent hyphae [15]. A hallmark is the presence of extensive angioinvasion with resultant vascular thrombosis and tissue necrosis. This angioinvasion leads to dissemination of hyphae from the original site of infection [18].

In the present study, each case of mixed infection and isolated aspergillus infection was noted. The presence of fruiting bodies gives the definite diagnosis of aspergillus at the histopathology level itself. Fruiting bodies are composed of vesicles and either 1 or 2 layers of phialides that produce conidia [20]. Special stains highlight the fungal wall with magenta colour in PAS and black colour in GMS [21].

Limitation(s)

This study has certain limitations. First, Potassium hydroxide (KOH) mount and culture reports were not included in the study. Though, confirmation of mucormycosis was done by relating presenting symptoms of the patient, KOH mount, CT/MRI scan and biopsy results. Second, the sample size of the study was small, due to the specimens received in the Pathology Department were included in the study and during the initial days of the surge of mucormycosis cases, few cases were referred to higher centres due to unavailability of equipment necessary for debridement owing to the rarity of the infection prior to COVID-19 pandemic.

CONCLUSION(S)

In the present study, it was observed that mucormycosis infection was most commonly seen in COVID-19 infected patients in post COVID-19 phase and also in minority of non COVID-19 infected

cases with prior debilitating conditions. Therefore, it was concluded that mucormycosis was positively associated with COVID-19 infected patients who have co-morbidities like diabetes mellitus and history of steroid usage.

REFERENCES

- [1] Mekki SO, Hassan AA, Falemban A, Alkotani N, Alsharif SM, Haron A, et al. Pulmonary mucormycosis: A case report of a rare infection with potential diagnostic problems. *Case Reports in Pathology*. 2020;2020:5845394.
- [2] Revannavar SM, Supriya PS, Samaga L, Vineeth VK. COVID-19 triggering mucormycosis in a susceptible patient: A new phenomenon in the developing world? *BMJ Case Reports*. 2021;14(4):e241663.
- [3] World Health Organisation (2021), Coronavirus Disease (COVID-19)/Mucormycosis, Retrieved from: [https://www.who.int/india/emergencies/coronavirus-disease-\(COVID-19\)/mucormycosis](https://www.who.int/india/emergencies/coronavirus-disease-(COVID-19)/mucormycosis).
- [4] Badiie P, Arastefar A, Jafarian H. Comparison of histopathological analysis, culture and polymerase chain reaction assays to detect mucormycosis in biopsy and blood specimens. *Iran J Microbiol*. 2013;5(4):406-10.
- [5] Singh AK, Singh R, Joshi SR, Misra A. Mucormycosis in COVID-19: A systematic review of cases reported worldwide and in India. *Diabetes Metab Syndr*. 2021;15(4):102146.
- [6] Kumar S, Anche ST, Syed M, Dutta J, Khan FA, Mali AP. Mucormycosis: A new threat in pandemic. *Journal of Advanced Medical and Dental Sciences Research*. 2021;9(6):131-35.
- [7] Asdaq SM, Rajan A, Damodaran A, Kamath SR, Nair KS, Zachariah SM, et al. Identifying mucormycosis severity in Indian COVID-19 patients: A nano-based diagnosis and the necessity for critical therapeutic intervention. *Antibiotics*. 2021;10(11):1308.
- [8] Sugar AM. Mucormycosis. *Clin Infect Dis*. 1992;14(Suppl 1):S126-29.
- [9] Biradar S, Patil SN, Kadeli D. Mucormycosis in a diabetic ketoacidosis patient: A case report. *J Clin Diagn Res*. 2016;10(5):OD09.
- [10] Camara-Lemarro CR, González-Moreno EI, Rodríguez-Gutiérrez R, Rendón-Ramírez EJ, Ayala-Cortés AS, Fraga-Hernández ML, et al. Clinical features and outcome of mucormycosis. *Interdisciplinary Perspectives on Infectious Diseases*. 2014;2014:562610.
- [11] Bala K, Chander J, Handa U, Punia RS, Attri AK. A prospective study of mucormycosis in north India: Experience from a tertiary care hospital. *Medical Mycology*. 2015;53(3):248-57.
- [12] Elzein F, Albarrag A, Kalam K, Arafah M, Al-Baadani A, Eltayeb N, et al. Mucormycosis: An 8-year experience of a tertiary care centre in Saudi Arabia. *J Infect Public Health*. 2020;13(11):1774-79.
- [13] Prakash H, Ghosh AK, Rudramurthy SM, Singh P, Xess I, Savio J, et al. A prospective multicenter study on mucormycosis in India: Epidemiology, diagnosis, and treatment. *Medical Mycology*. 2019;57(4):395-402.
- [14] Patel A, Kaur H, Xess I, Michael JS, Savio J, Rudramurthy S, et al. A multicentre observational study on the epidemiology, risk factors, management and outcomes of mucormycosis in India. *Clin Microbiol Infect*. 2020;26(7):944-e49.
- [15] Frank KM, McAdam AJ. *Infectious Diseases*. In: Kumar, Abbas, Aster (Eds), Robbins & Cotran pathologic basis of disease, 10th edition, Faridabad: RELIX India Private Limited; 2021, Pp. 387-88.
- [16] Hernández JL, Buckley CJ. Mucormycosis. [Updated 2020 Jun 26]. *Stat Pearls* [Internet]. Treasure Island (FL): Stat Pearls Publishing. 2021.
- [17] Mehta S, Pandey A. Rhino-orbital mucormycosis associated with COVID-19. *Cureus*. 2020;12(9):e10726.
- [18] Spellberg B, Edwards Jr J, Ibrahim A. Novel perspectives on mucormycosis: Pathophysiology, presentation, and management. *Clin Microbiol Rev*. 2005;18(3):556-69.
- [19] Sravani T, Uppin SG, Uppin MS, Sundaram C. Rhinocerebral mucormycosis: Pathology revisited with emphasis on perineural spread. *Neurology India*. 2014;62(4):383.
- [20] Anila KR, Somanathan T, Mathews A, Jayasree K. Fruiting bodies of Aspergillus: An unusual finding in histopathology. *Lung India*. 2013;30(4):357-59.
- [21] Guarner J, Brandt ME. Histopathologic diagnosis of fungal infections in the 21st century. *Clin Microbiol Rev*. 2011;24(2):247-80.

PARTICULARS OF CONTRIBUTORS:

1. Postgraduate Student, Department of Pathology, Government Medical College, Srikakulam, Andhra Pradesh, India.
2. Associate Professor and Incharge Head, Department of Pathology, Government Medical College, Srikakulam, Andhra Pradesh, India.
3. Associate Professor, Department of Pathology, Government Medical College, Srikakulam, Andhra Pradesh, India.
4. Assistant Professor, Department of Pathology, Government Medical College, Srikakulam, Andhra Pradesh, India.
5. Assistant Professor, Department of Pathology, Government Medical College, Srikakulam, Andhra Pradesh, India.

NAME, ADDRESS, E-MAIL ID OF THE CORRESPONDING AUTHOR:

Rajani Kuna,
Plot No: 343, Purushotham Nagar Colony, Srikakulam, Andhra Pradesh, India.
E-mail: rajani2dss@gmail.com

AUTHOR DECLARATION:

- Financial or Other Competing Interests: None
- Was Ethics Committee Approval obtained for this study? Yes
- Was informed consent obtained from the subjects involved in the study? NA
- For any images presented appropriate consent has been obtained from the subjects. NA

PLAGIARISM CHECKING METHODS: [Jan H et al.]

- Plagiarism X-checker: Nov 19, 2021
- Manual Googling: Dec 08, 2021
- iThenticate Software: Feb 08, 2022 (9%)

ETYMOLOGY: Author Origin

Date of Submission: **Nov 11, 2021**

Date of Peer Review: **Dec 09, 2021**

Date of Acceptance: **Feb 15, 2022**

Date of Publishing: **Mar 01, 2022**