

Response of Broilers to Dietary *Moringa oleifera* Leaf, Raw and Cooked Seed Meal and Synthetic Antibiotics

I. O. Adejumo^{1*}, C. O. Adetunji², C. O. Olopade¹ and K. O. George¹

¹Department of Animal Science, Landmark University, Omu-Aran, Nigeria.

²Department of Microbiology, Landmark University, Omu-Aran, Nigeria.

Authors' contributions

This work was carried out in collaboration among all authors. Authors IOA and COA designed the study and performed the laboratory analyses. Authors COO and KOG carried out the feeding trial. All authors read and approved the final manuscript.

Article Information

DOI: 10.9734/AJEA/2016/25302

Editor(s):

(1) Hugo Daniel Solana, Department of Biological Science, National University of Central Buenos Aires, Argentina.

(2) Zhen-Yu Du, School of Life Science, East China Normal University, China.

Reviewers:

(1) Adeyinka O. Akintunde, University of Ilorin, Ilorin, Nigeria.

(2) K. E. Akande, Abubakar Tafawa Balewa University, Bauchi State, Nigeria.

(3) Wagner Loyola, Brazilian Agricultural Research Corporation, Brazil.

(4) F. E. Sola-Ojo, University of Ilorin, Nigeria.

Complete Peer review History: <http://sciencedomain.org/review-history/14481>

Original Research Article

Received 27th February 2016

Accepted 19th April 2016

Published 6th May 2016

ABSTRACT

The effects of *Moringa oleifera* leaf meal and raw and cooked seed meal as a replacement for synthetic antibiotic (tetracycline) on carcass characteristics, heart and liver histology of broiler chickens were assessed in a 7-week feeding trial.

The design of the study was a completely randomised design. There were 5 treatments: negative control (D1), positive control (D2), treatments 3, 4 and 5 (D3, D4 and D5) contained 0.25 g/kg of feed of raw air-dried *Moringa oleifera* leaf meal, 0.25 g/kg of feed of raw air-dried and cooked air-dried *Moringa oleifera* seed meal respectively. Each treatment had four replicates of 8 birds per replicate.

The results of the study indicated no significant difference across the treatments for most of the carcass characteristics. Birds on D1 recorded the lowest mean values for heart (6.94 g), spleen (1.56 g), wings (121.00 g) and drumstick (154.24 g). Birds on D4 compared well with those on D2 in

*Corresponding author: E-mail: smogisaac@gmail.com;

terms of drumstick, spleen, heart and wings. No visible lesions were observed in the heart histology of the experimental birds. Liver photomicrograph of birds on D1 indicated mild dissociation of hepatic cords, those on D2 showing closely-packed hepatic plates. Those on D3 showed a few foci of mild random single-cell hepatocellular necrosis. Those on D4 showing no visible lesions while those on D5 showed severe diffuse fatty change of hepatocytes with a few normal hepatocytes. Birds on raw *Moringa oleifera* seed meal compared well with those on synthetic antibiotics, however, the liver histology of those on synthetic antibiotics indicated potential danger of liver damage.

Keywords: Antibiotics; broilers; feeding trial; histology; *Moringa oleifera*.

1. INTRODUCTION

Food safety and security are a global concern; hence, there is the need to ensure that the dietary animal protein requirement is met. The poultry industry remains an important food supplier in the world. Chicken meat represents an important source of animal proteins [1]. Apart from feed cost, disease outbreak is another important factor mitigating against poultry production and productivity in Sub-Saharan Africa. Outbreaks usually result in great economic losses as a result of the accompanied morbidity, mortality, destruction of the intestinal epithelium which consequently results in reduced body weight gain (BWG), feed conversion ratios (FCR) and reduced egg production [2,3,4]. Therefore, the existence and control of disease outbreak in chickens remain a threat to animal food safety and security in sub-Saharan Africa which call for urgent attention.

Several approaches have been used to control disease outbreak in poultry flocks such as improved animal husbandry, higher hygiene standards, the use of drugs and vaccination. However, the spread of the disease is heightened by the development of resistance to some of the drugs by the causative protozoan parasites and the escalating cost of drug. Consumers' request for poultry products that are free from residual drugs is another factor limiting the use of chemotherapeutic agents or antibiotics [5].

Wild plants for reasons of cost, availability and accessibility have been exploited in Africa in the past in order to bring solution to numerous health challenges of man. *Moringa oleifera* is one of the numerous plants being exploited. *Moringa oleifera* is believed to contain an antibacterial agent 4(α -L-rhamnosyloxy) benzyl isothiocyanate, which is a plant synthesised derivative of benzyl isothiocyanates [6]. Anticoccidial property of *Moringa oleifera* extracts

had also been reported [7]. It then becomes necessary to test the efficacy of *Moringa oleifera* leaf and differently processed seed meal as a potential replacement for synthetic antibiotics in broiler production in order to assess their comparative effects and toxicity.

2. MATERIALS AND METHODS

The feeding trial was carried out at the Poultry Unit of Teaching and Research Farm of Landmark University, Nigeria. Landmark University is located in Omu-Aran, which geographical coordinates are 8° 8' 0" North, 5° 6' 0" East. There were 5 treatments: negative control (D1) which contained neither *Moringa oleifera* leaf or seed meal; positive control (D2), treated with 0.25% tetracycline in water; treatments 3, 4 and 5 (D3, D4 and D5) contained 0.25 g/kg of feed of raw air-dried *Moringa oleifera* leaf meal, 0.25 g/kg of feed of raw air-dried and cooked air-dried *Moringa oleifera* seed meal respectively. Each treatment had four replicates of 8 birds (arbor acre) per replicate. Fresh feeds and clean, cool water were supplied to the birds *ad libitum* throughout the period of the study. The study lasted for 7 weeks. Only birds on D2 were given the synthetic antibiotic throughout the period of the study. The proximate composition of the *Moringa oleifera* leaves and experimental diets were carried out using the method of the AOAC [8]. Gross experimental composition and determined chemical compositions of the experimental diets are presented in Tables 1 and 2 respectively.

At the end of experimental period, 2 birds from each replicate were randomly picked up and sacrificed. The birds were taken off feed 12 hours before slaughter. The organs and carcass in each group were separated into different parts and weighed: leg, shank, wing, thigh, breast, and drumstick. The organs: liver, heart, gizzard and spleen were also weighed using the sensitive scale.

Table 1. Gross composition of experimental diet fed to broiler chickens

Ingredients (%)	Starter	Finisher
Maize	54.00	66.00
Soya bean	31.00	20.00
Fish meal (72% CP)	3.00	2.00
Palm oil	1.50	0.00
Wheat offal	6.00	8.00
Bone meal	2.00	2.00
Oyster shell	1.00	1.00
Salt	0.25	0.25
Methionine	0.25	0.25
Lysine	0.25	0.25
Premix	0.25	0.25

ME= Metabolisable energy; Premix contains: vit A (1000000IU); vit D3 (3000000 IU); vit E (30000 IU); vit K (2300 mg); vit B2 (5000 mg); vit C (2000 mg); niacin (30000mg); panthotenic acid (8000 mg); vit B6 (3000 mg); vit B12 (16 mg); folic acid (800 mg); biotin (600 mg); choline chloride (200000 mg); cobalt (200 mg); copper (600 mg); iodine (25000 mg); iron (20000 mg); manganese (85000 mg); selenium (120 mg); zinc (50000 mg); antioxidant (1250 mg). D1 = negative control, D2 = 0.25% of synthetic antibiotics (oxytetracycline) in water, D3 = 0.25 g of raw *Moringa oleifera* leaf meal /kg feed, D4 = 0.25 g of raw *Moringa oleifera* seed meal /kg feed, D5 = 0.25 g of cooked *Moringa oleifera* seed meal /kg feed

Table 2. Determined chemical composition of experimental diets (finisher phase)

Nutrients (%)	D1	D2	D3	D4	D5
Moisture	10.56	10.59	10.75	10.76	10.70
Crude protein	19.66	18.35	18.80	18.88	18.73
Crude fibre	2.50	2.37	2.44	2.36	2.44
Fat	5.54	4.88	5.47	5.46	5.70
Ash	10.69	8.92	10.26	10.01	10.34
Calcium	0.62	0.38	0.66	0.68	0.65
Phosphorus	0.78	0.74	0.75	0.75	0.76
Starch	37.21	39.28	37.89	37.93	38.00
Total sugar	3.42	3.57	3.45	3.44	3.54

D1 = Negative control, D2 = 0.25% of synthetic antibiotics (oxytetracycline) in water, D3 = 0.25 g of raw *Moringa oleifera* leaf meal/kg feed, D4 = 0.25 g of raw *Moringa oleifera* seed meal /kg feed, D5 = 0.25 g of cooked *Moringa oleifera* seed meal /kg feed

Hearts and livers of experimental birds were harvested, preserved in 10% buffered formalin solution and analysed for histological studies. Histologic sections were prepared from the livers and were fixed in bouin's solution (mixture of 75 mL of saturated picric acid, 25 mL of 40% formaldehyde and 5 mL of glacial acetic acid) for 12 hours. This was embedded in paraffin using conventional method and cut into 5µm thick sections and stained using hematoxylin- eosin dye and finally mounted in diphenyl xylene [9]. The sections were then observed under the microscope for histopathological changes in liver architecture and their photomicrographs were taken.

Data obtained were analysed within the framework of general linear models of analysis using Statistical Analysis System [10], while

significant means were separated using Duncan's multiple range test of same software.

3. RESULTS AND DISCUSSION

Table 3 shows the carcass characteristics of experimental birds, while Figs. 1 and 2 show the photomicrograph of hearts and livers of experimental animals. The results of the study indicated no significant difference across the treatments for most of the carcass characteristics. Birds on D1 recorded the lowest mean values for heart (6.94 g), spleen (1.56 g), wings (121.00 g) and drumstick (154.24 g). Birds on D4 compared well with those on D2 in terms of drumstick, spleen, heart and wings. No visible lesions were observed in the heart histology of the experimental birds. Liver photomicrograph of birds on D1 indicated mild dissociation of hepatic

cords, those on D2 showing closely-packed hepatic plates. Those on D3 showed a few foci of mild random single-cell hepatocellular necrosis. Those on D4 showing no visible lesions while those on D5 showed severe diffuse fatty change of hepatocytes with a few normal hepatocytes.

Growth performance characteristics of the birds treated with synthetic antibiotics (D2) (1.57 kg/bird) and those fed with diet supplemented with raw air-dried *Moringa oleifera* (D4) (1.58 kg/bird) had significantly ($P=0.05$) higher body weight gain compared with those fed negative control (1.45 kg/bird). Body weight gain of birds in D5 (1.51 kg/bird) and D3 (1.45 kg/bird) was statistically similar to those of negative control (1.45 kg/bird). Feed intake was higher for those fed D2 (2.09 kg/bird), D4 (2.16 kg/bird) and D5 (2.17 kg/bird) than the negative control (1.90 kg/bird). Feed intake by birds on D3 (raw moringa leaf meal) (2.01 kg/bird) was statistically similar to that of negative control (1.90 kg/bird), as recorded in another paper. Ologhobo et al. [11] earlier reported that *Moringa oleifera* leaf meal did not result in significance difference among treatments for most of the carcass

parameters of broilers measured. The result of the findings by Nuhu et al. [12] earlier showed that there were no significant differences among treatments for carcass characteristic for weaner rabbits fed *Moringa oleifera* leaf meal. Ayssiwede et al. [13] also reported that there were no significant differences for carcass parameters across treatments except for lung and spleen weights which were significantly increased in birds fed 8% and 16% *Moringa oleifera* leaf meal. The authors reported that inclusion of Moringa leaf meal had no adverse effect on dressing carcass, liver weight, and all organs weight ratios. Also, Zanu et al. [14] found out that none of the parameters measured for carcass characteristics in birds fed diets containing *Moringa oleifera* leaf meal was affected significantly.

It has been observed that antibiotics are a common cause of drug-induced liver injury [15]. Although the frequency of serious antibiotic-induced hepatotoxicity is low compared with the amounts prescribed each year—population-based estimates suggest that it occurs in <5 per 100000 population [16]. Antibiotic-induced

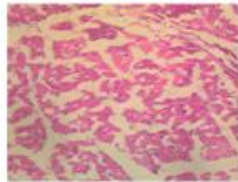


Fig.1a. Heart photomicrograph of birds on D1 showing no visible lesions (NVL) and normal cardiomyocytes

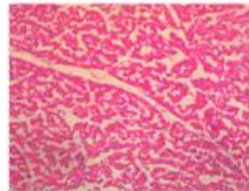


Fig.1b. Heart photomicrograph of birds on D2 showing NVL and normal cardiomyocytes

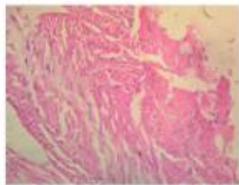


Fig.1c. Heart photomicrograph of birds on D3 showing NVL and normal cardiomyocytes

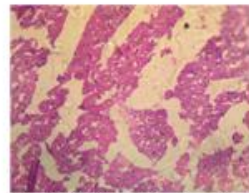


Fig.1d. Heart photomicrograph of birds on D4 showing NVL and normal cardiomyocytes

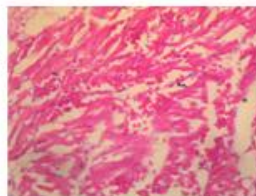


Fig.1e. Heart photomicrograph of birds on D5 showing NVL and normal cardiomyocytes

Mg X 400

Fig. 1. Heart photomicrographs of birds fed experimental diets

Table 3. Carcass characteristics of broilers fed diets supplemented with *Moringa oleifera* leaf and seed meal

Parameters	D1	D2	D3	D4	D5	SEM
Live weight (kg/bird)	1.58	1.72	1.59	1.70	1.64	0.03
Slaughtered weight (kg/bird)	1.52	1.60	1.47	1.60	1.54	0.02
Defeathered weight (kg/bird)	1.46	1.62	1.52	1.62	1.55	0.03
Dressed weight (kg/bird)	1.15	1.23	1.21	1.27	1.23	0.02
Visceral (kg)	0.26	0.27	0.28	0.28	0.24	0.01
Drumstick (g)	154.24 ^b	215.17 ^a	173.82 ^{ab}	175.58 ^{ab}	166.25 ^{ab}	10.25
Liver (g)	51.89	61.93	48.27	51.47	51.65	2.32
Spleen (g)	1.56 ^b	1.82 ^{ab}	1.79 ^{ab}	2.05 ^a	1.66 ^{ab}	0.08
Abdominal fat (g)	25.93	19.75	20.19	23.34	20.36	1.19
Empty gizzard (g)	30.31	31.76	30.69	33.80	32.32	0.62
Heart(g)	6.94 ^b	8.73 ^a	7.63 ^{ab}	7.93 ^{ab}	7.76 ^{ab}	0.29
Wings (g)	121.00 ^b	140.20 ^{ab}	134.95 ^{ab}	145.43 ^a	133.18 ^{ab}	4.09
Legs (g)	65.33	77.09	65.42	73.06	70.94	2.27
Shank length (cm)	7.75	7.50	7.83	7.92	7.58	0.08
Breast (g)	306.33	321.57	308.33	310.13	337.06	5.73
Thigh (g)	180.22	169.25	181.06	192.83	181.20	3.73

Means with different superscripts within the same rows are significantly different. P= 0.05.

D1 = Negative control, D2 = 0.25% of synthetic antibiotics (oxytetracycline) in water, D3 = 0.25 g of raw *Moringa oleifera* leaf meal/kg feed, D4 = 0.25 g of raw *Moringa oleifera* seed meal/kg feed, D5 = 0.25 g of cooked *Moringa oleifera* seed meal/kg feed

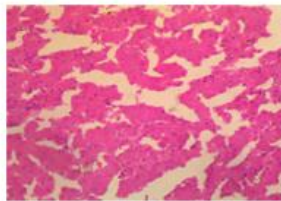


Fig.2a. Liver photomicrograph of birds on D1 showing mild dissociation of hepatic cords

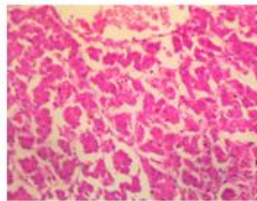


Fig.2b. Liver photomicrograph of birds on D2 showing closely-packed hepatic plates.

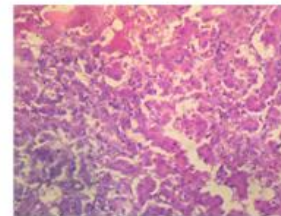


Fig. 2c. Liver photomicrograph of birds on D3 showing a few foci of mild random single-cell hepatocellular necrosis

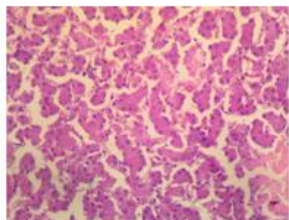


Fig.2d. Liver photomicrograph of birds on D4 showing no visible lesions

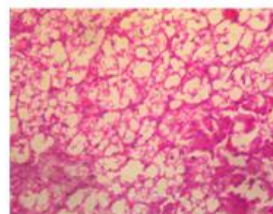


Fig. 2e. Photomicrograph of birds on D5 showing severe diffuse fatty change of hepatocytes with a few normal hepatocytes

Mg x400

Fig. 2. Liver photomicrographs of birds fed experimental diets

hepatotoxicity is usually asymptomatic, transient and associated with only mild hepatic impairment [17]. Asha et al. [18] earlier reported the effect of tetracycline at two doses of 50 and

200 mg kg⁻¹ daily on pancreatic and liver tissue function for 14 and 21 days in adult male albino rats. The authors found out that free radical levels and reduced glutathione were within the

normal range at the 50 mg kg⁻¹ level in the liver and significant changes were observed at 200 mg kg⁻¹. The antioxidant status was unaffected in liver after treatment with tetracycline at the 50 mg kg⁻¹ level and a significant decrease was observed at the higher dose. The results revealed the safe nature of tetracycline with respect to the liver at the lower dose tested, whereas, both the higher and lower doses seem to have detrimental effect on the pancreas. Nilanjan et al. [19] noted that *Moringa oleifera* leaf extract prevented and cured high fat diet-induced liver damage, and observed normal hepatic architecture in mice exposed to *Moringa oleifera* leaf extract.

4. CONCLUSION

The research of new ways to control infectious diseases has been viewed as an important means of combating hunger for human populations. The use of synthetic antibiotics as growth promoters may lead to the selection of resistant micro-organisms amidst other challenges which could cause future damage to human health. It was inferred from the results of the present study that birds on raw *Moringa oleifera* seed meal compared well with those on synthetic antibiotics, however, the liver histology of those on synthetic antibiotics indicated potential danger of liver damage. There is the need to assess the effects of differently processed *Moringa oleifera* seed and leaf meal on animals challenged against common pathogens in order to fully establish their microbial properties.

ETHICAL APPROVAL

Principles of laboratory animal care (NIH publication No. 85-23, revised 1985) were followed. The experiment was examined and approved by the appropriate ethics committee of the university before the commencement.

COMPETING INTERESTS

Authors have declared that no competing interests exist.

REFERENCES

1. Bogosavljevic-Boskovic S, Mitrovic S, Djokovic R, Doskovic V, Djermanovic V. Chemical composition of chicken meat produced in extensive indoor and free range rearing systems. Afr. J. Biotechnol. 2010;9(53):9069-9075.
2. Min W, Dalloul RA, Lillehoj HS. Application of biotechnological tools for coccidian vaccine development. J. Vet. Sci. 2004;5: 279–288.
3. Dalloul RA, HS Lillehoj. Recent advances in immunomodulation and vaccination strategies against coccidiosis. Avian Dis. 2005;49:1–8.
4. Shivaramaiah C, Barta JR, Hernandez-Velasco X, Tellez G, Hargis BM. Coccidiosis: Recent advancement in the immunobiology of *Eimeria* species, preventive measures, and the importance of vaccination as a control tool against apicomplexan parasites. Veterinary Medicine: Research and Reports. 2014;23-34.
5. Harper CG, Makatouni A. Consumer perception of organic food production and farm animal welfare. Br. Food J. 2002; 104:287–299.
6. Valarmathy K, Babu PS, Abhilash M. Antimicrobial activity of ethanolic extracts of various plant leaves against selected microbial species. Electronic Journal of Environmental Agricultural and Food Chemistry. 2010;9(8):1378-1382.
7. Ola-Fadunsin SD, Ademola IO. Anticoccidial effects of *Morinda lucida* acetone extracts on broiler chickens naturally infected with *Eimeria* species. Pharm Biol. 2014;52(3):330-334.
8. AOAC. Official Methods of Analysis. 16th edn. Association of Official Analytical Chemists, Arlington, VA, 1996.
9. Galighor AE, Koziff EN. Essentials of Practical Micro technique. 2nd ed. New York: Lea and Febriger 210; 1976.
10. SAS Institute Inc. SAS/STAT user's guide: Version 9. 4th edn. SAS Institute Inc., Cary, NC, USA; 2003.
11. Ologhobo AD, Akangbe EI, Adejumo IO, and Adeleye O. Effect of *Moringa oleifera* leaf meal as replacement for oxytetracycline on carcass characteristics of the diets of broiler chickens. Annual Research & Review in Biology. 2014;4(2): 423-431.
12. Nuhu F. Effect of Moringa leaf meal (MOLM) on nutrient digestibility, growth, carcass and blood indices of weaner rabbits. Msc. Thesis, Animal Science Department of the Faculty of Agriculture and Natural Resources, Kwame Nkrumah

- University of Science and Technology, Kumasi. 2010;107.
13. Ayssiwede SB, Dieng A, Bello H, Chrysostome CAAM, Hane MB, Mankor A, Dahouda M, Houinato MR, Hornick JL, Missohou A. Effects of *Moringa oleifera* (Lam.) leaves meal incorporation in diets on growth performance, carcass characteristics and economic results of growing indigenous Senegal chickens. Pakistan Journal of Nutrition. 2011;10(2): 1132-1145.
 14. Zanu HK, Asiedu P, Tampuori M, Asada M, Asante I. Possibilities of using moringa (*Moringa oleifera*) leaf meal as a partial substitute for fishmeal in broiler chickens diet. Online Journal of Animal Feed Resources. 2012; 2(1):70-75. Available:<http://www.science-line.com/index>
 15. Robles M, Andrade RJ. Hepatotoxicidad por antibioticos: Actualizacion en 2008 [in Spanish (Hepatotoxicity by antibiotics: Update in 2008); abstract in English] Rev Esp Quimioter. 2008;21:224–33.
 16. Polson JE. Hepatotoxicity due to antibiotics. Clin Liver Dis. 2007;11:549–61.
 17. Thiim M, Friedman LS. Hepatotoxicity of antibiotics and antifungals. Clin Liver Dis. 2003;7:381–99.
 18. Asha KK, Sankar TV, Viswanathan Nair PG. Effect of tetracycline on pancreas and liver function of adult male albino rats. J Pharm Pharmacol. 2007;59(9):1241-8.
 19. Nilanja D, Kunal S, Santinath G, Bernard F, Sanjit D. *Moringa oleifera* Lam. leaf extract prevents early liver injury and restores antioxidant status in mice fed with high-fat diets. Indian Journal of Experimental Biology. 2012;50:404-412.

© 2016 Adejumo et al.; This is an Open Access article distributed under the terms of the Creative Commons Attribution License (<http://creativecommons.org/licenses/by/4.0>), which permits unrestricted use, distribution, and reproduction in any medium, provided the original work is properly cited.

Peer-review history:
The peer review history for this paper can be accessed here:
<http://sciencedomain.org/review-history/14481>